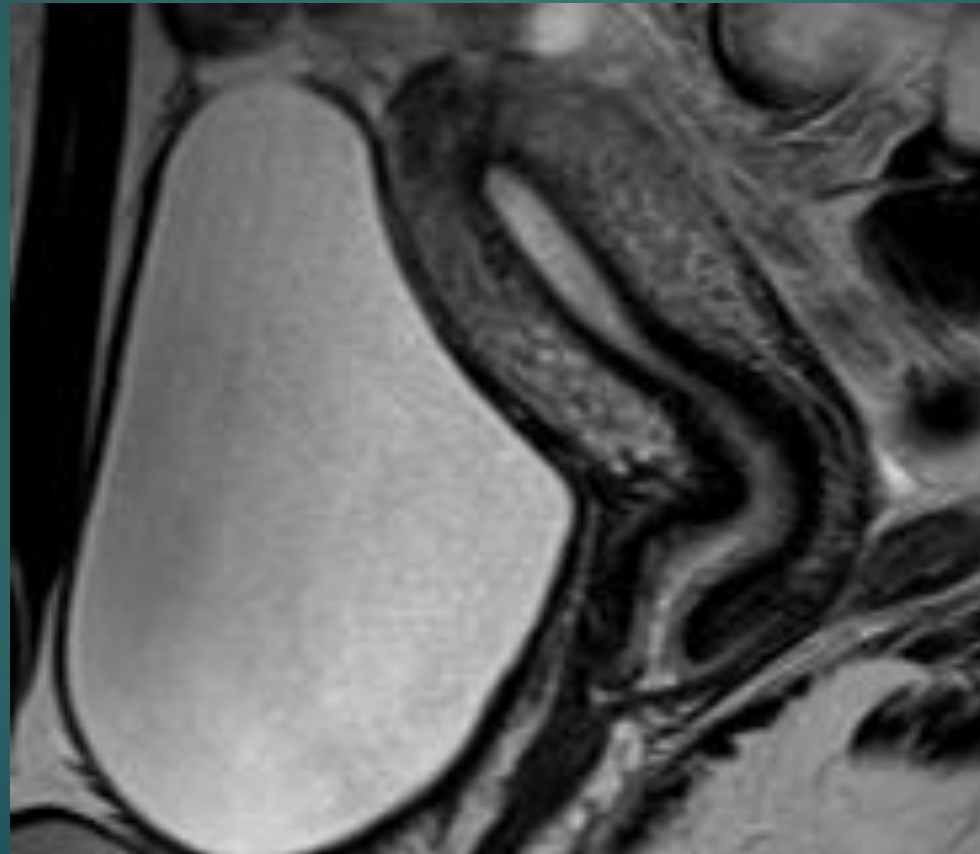


JİNEKOLOJİK PATOLOJİLERDE MRG

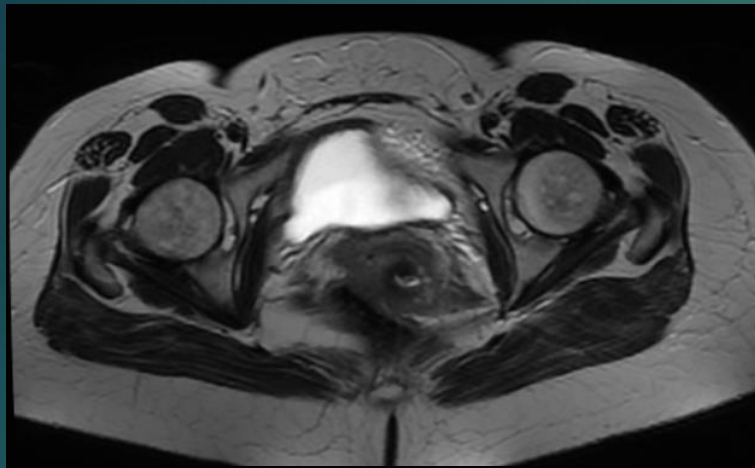Dr.Ümit TÜZÜN

ANATOMI

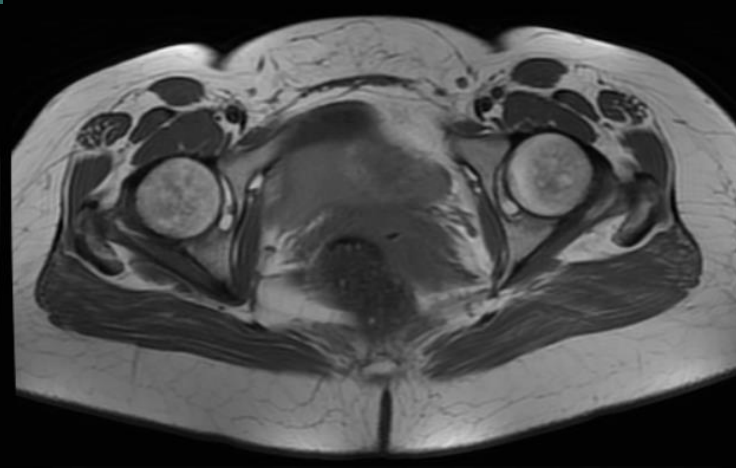


PROTOKOL

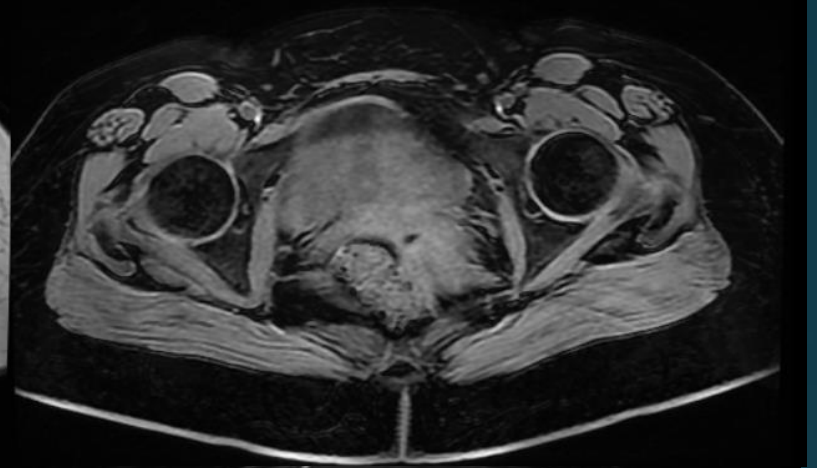T2W



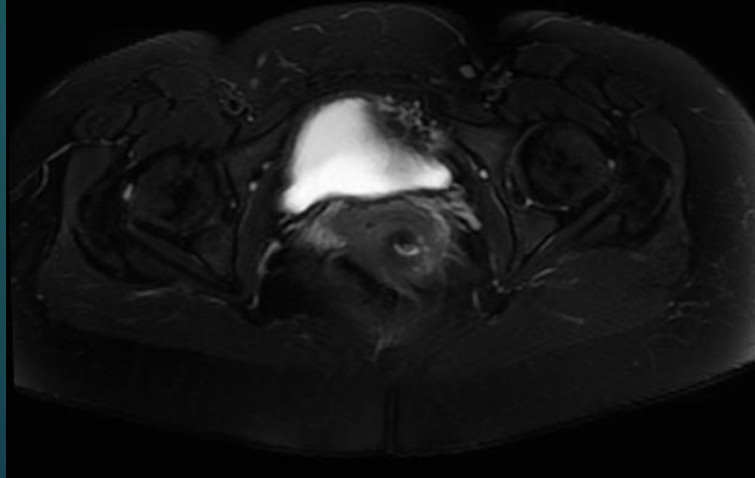
T1W



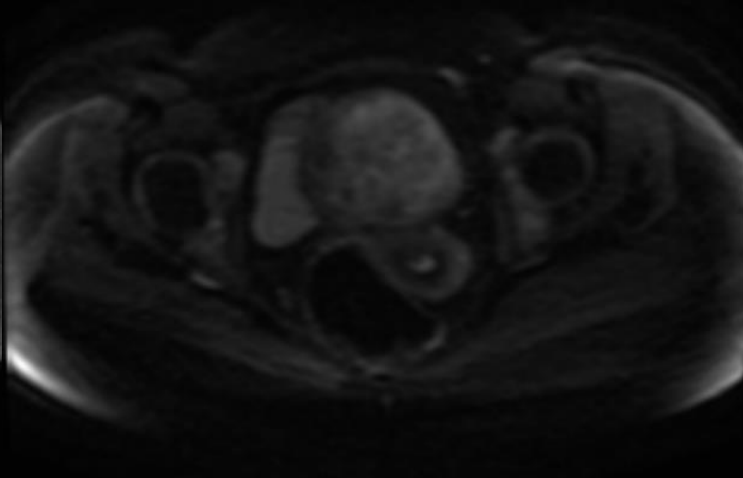
T1W FAT SAT



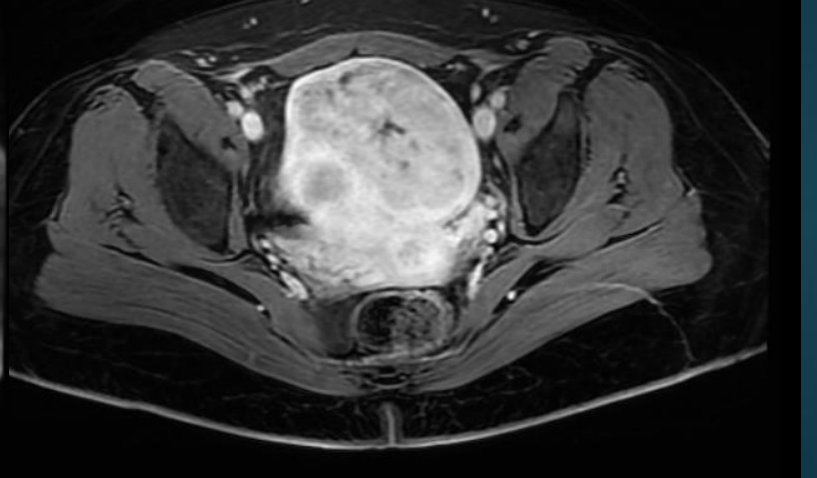
T2W FAT SAT


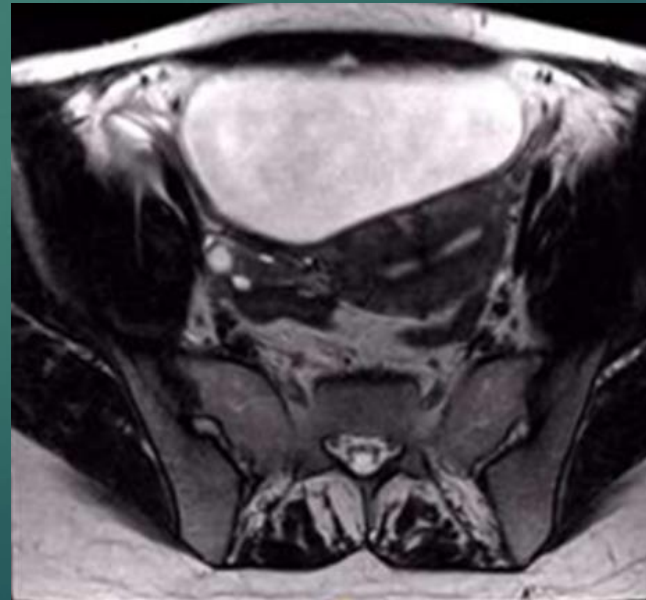
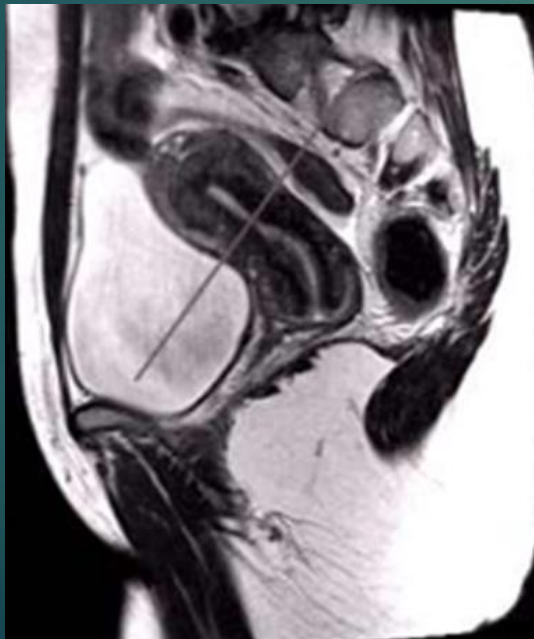
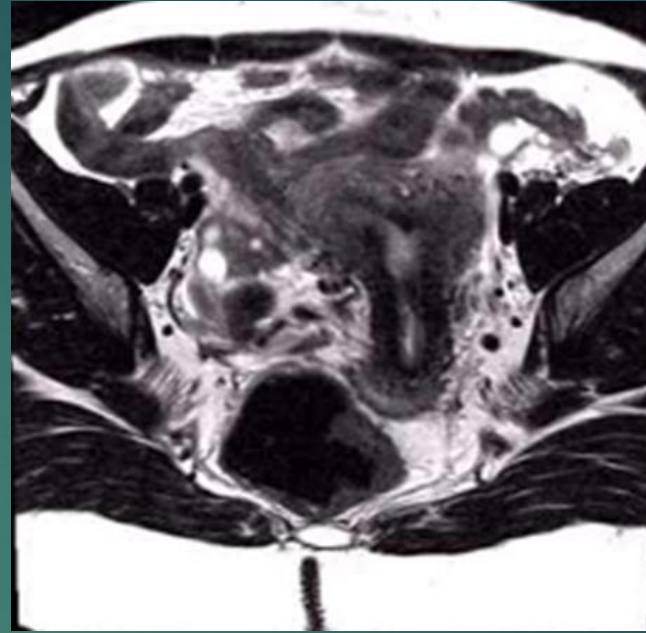
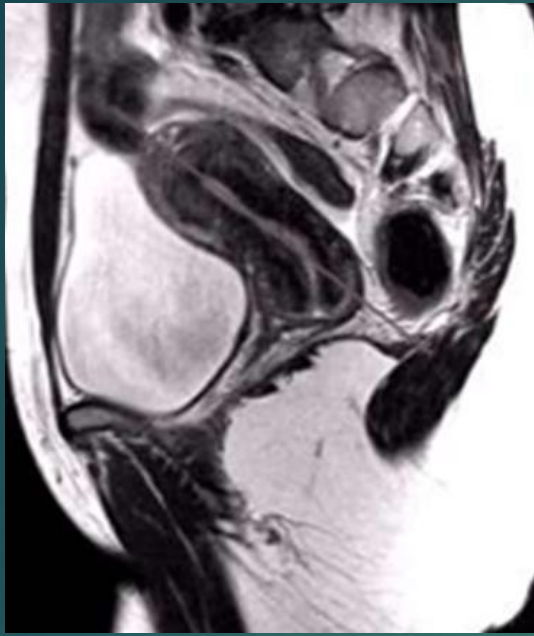


DİFÜZYON

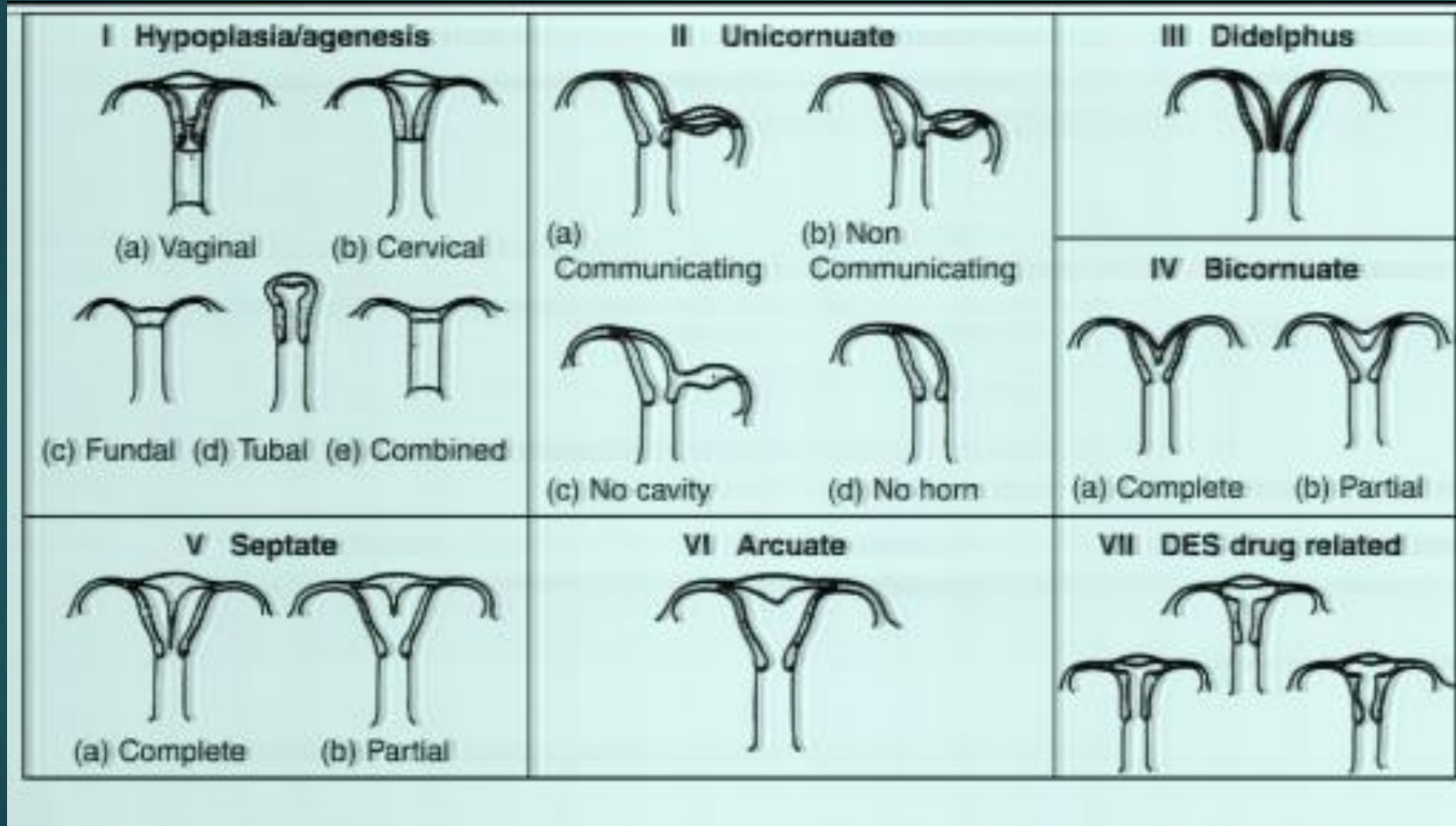


POSTKONTRAST T1W FAT SAT



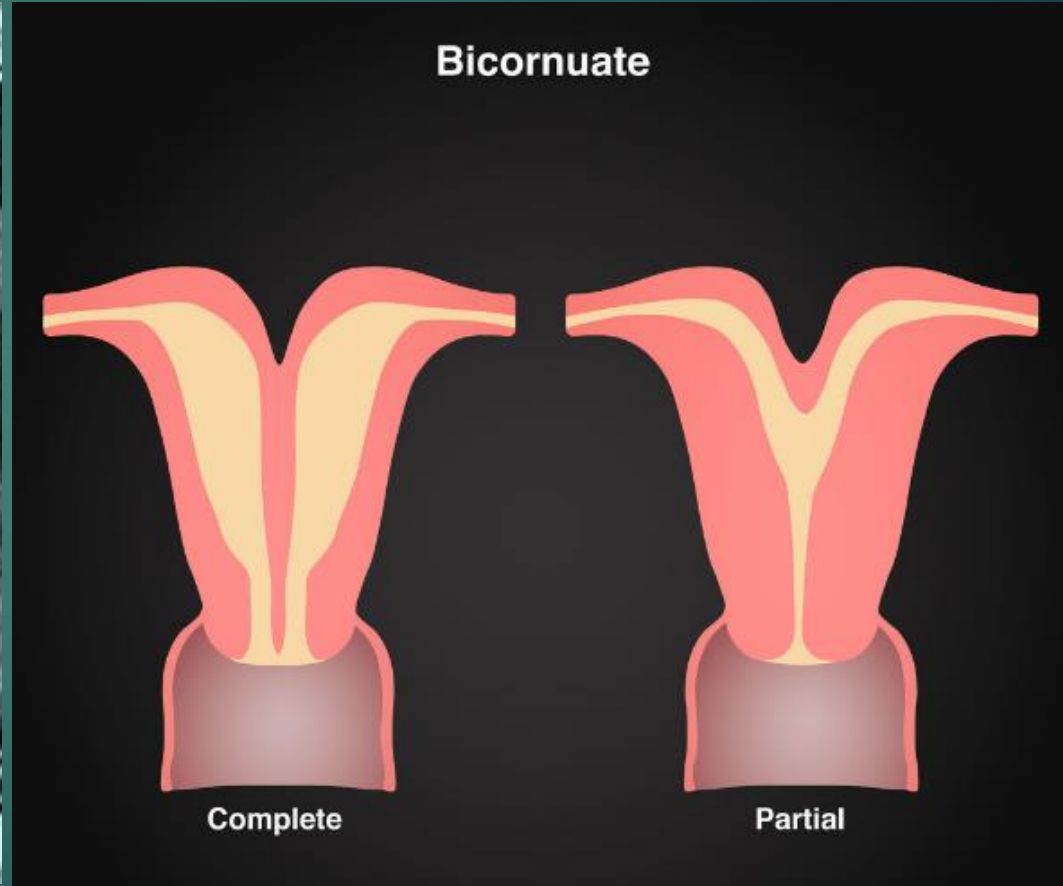
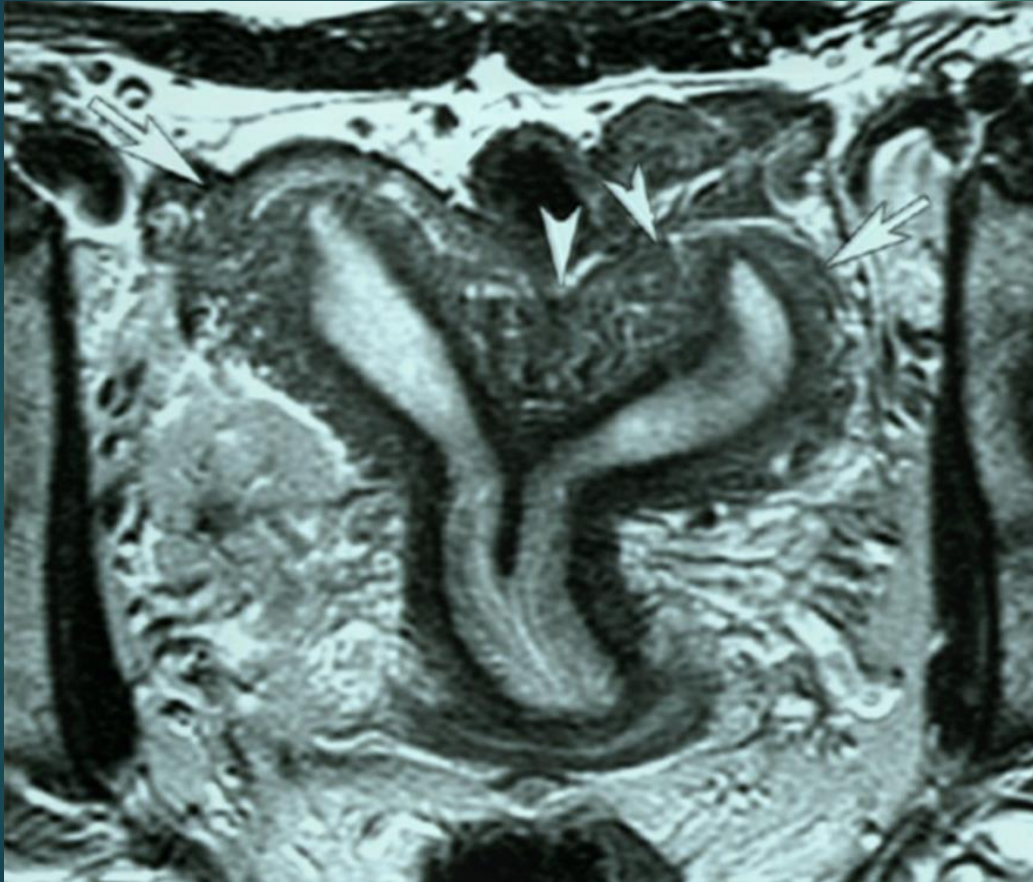

KONJENİTAL ANOMALİLER

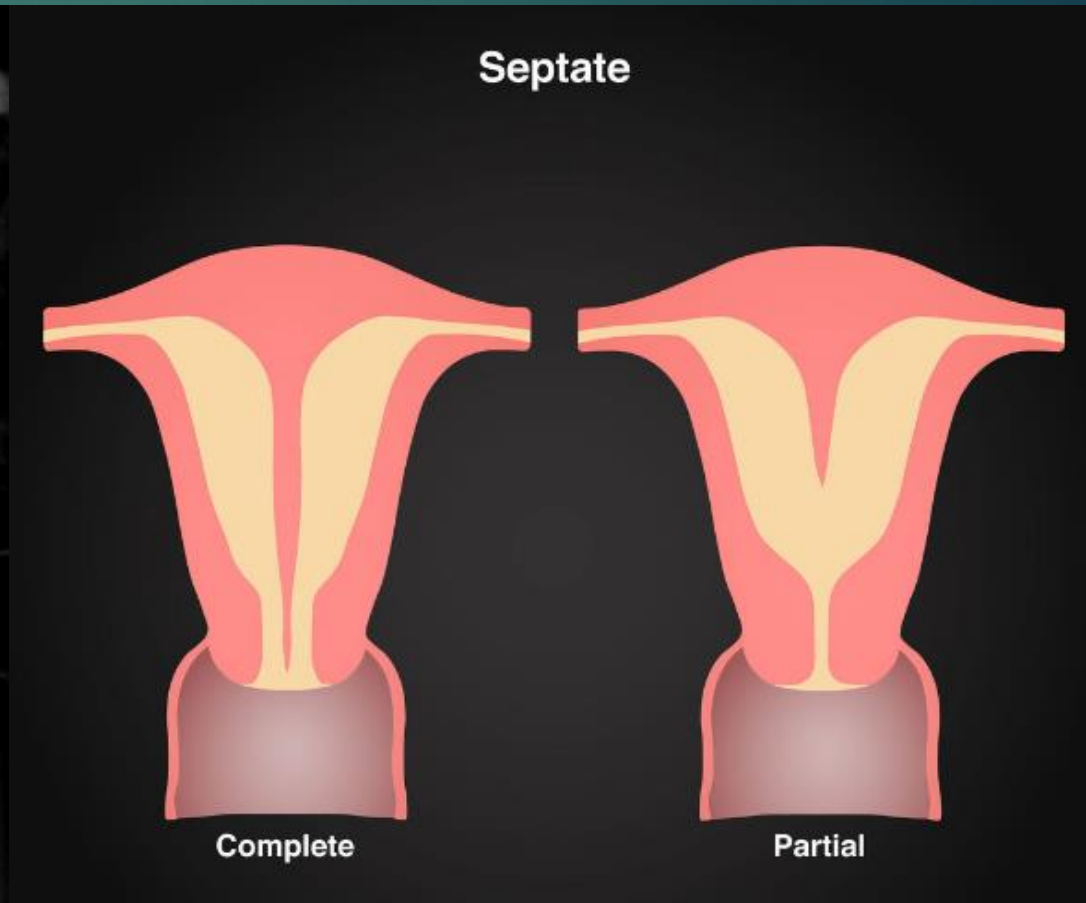
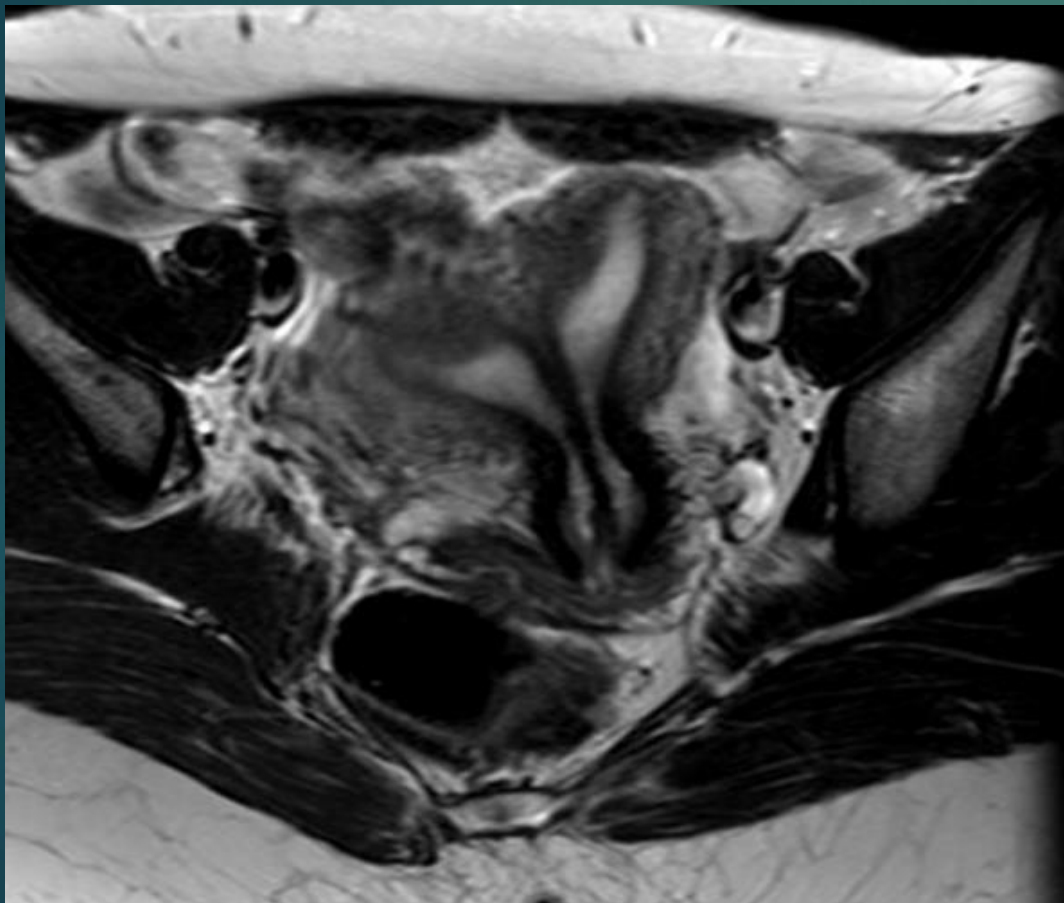


- ▶ Doğru tiplene!!!!
- ▶ Anomali tipleri arasında sağlıklı gebelik beklentisi oranları ve tedavi yaklaşımları arasında belirgin farklılıklar var.
- ▶ HSG ilk istenen tetkik ancak USG ile birlikte subtipler arasındaki ayırımıda sınırlı rolü var.
- ▶ MR tanıda altın standart.
- ▶ Septat-bikornuat uterus ayırımı---(fundus dış konturu!!!!)

Bicornis unicollis

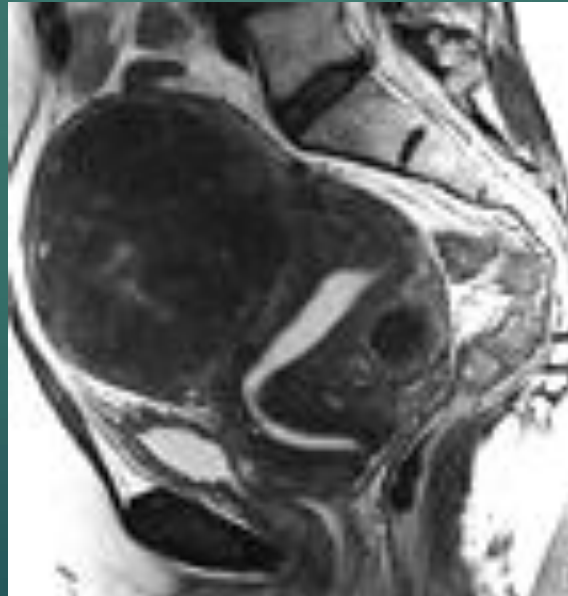


Komplet septat uterus



MYOM

- ▶ Uterusun en sık rastlanılan tümörü
- ▶ Preop haritalama
- ▶ Komplikasyonlar...Dejenerasyon (hyalin,kistik,miksoid,kırmızı),komşu organ basısı,torsiyon



Intramural

5 Subserosal and $\geq 50\%$ intramural

4 100% Intramural

Submucosal

Pedunculated intracavity
< 50% intramural

0

1

3 100% intramural and endometrial contact

2 $\geq 50\%$ Intramural

Subserosal

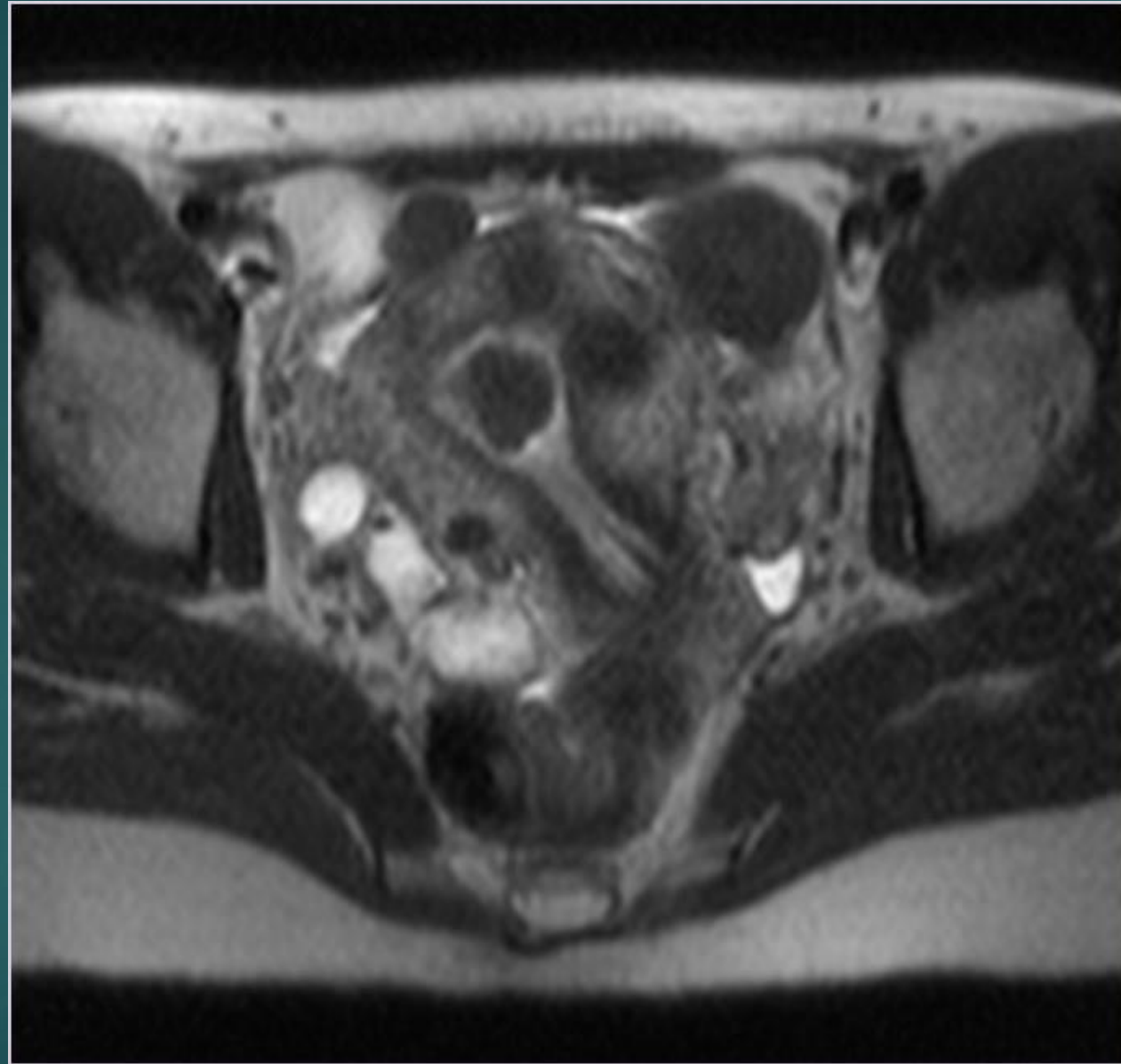
6 Subserosal and < 50% intramural

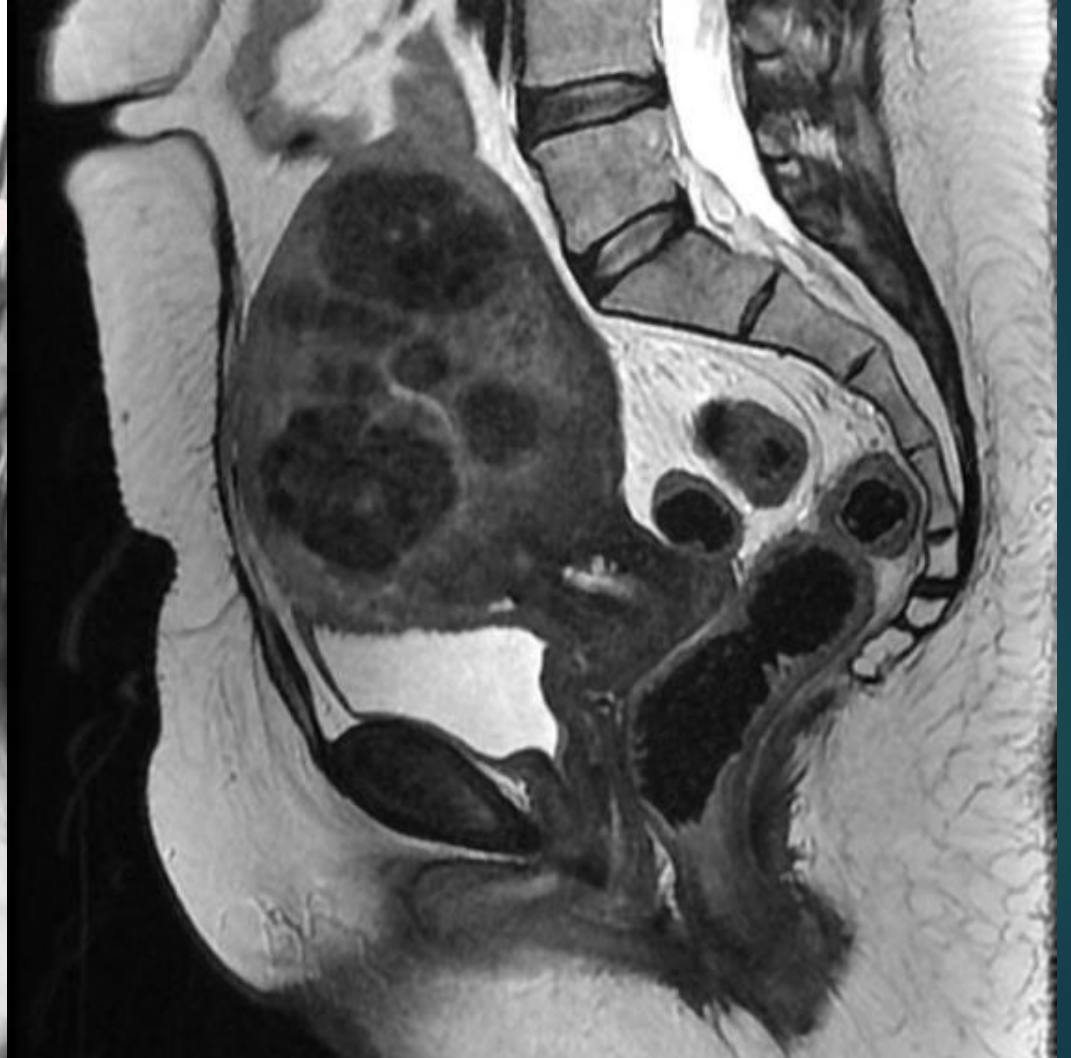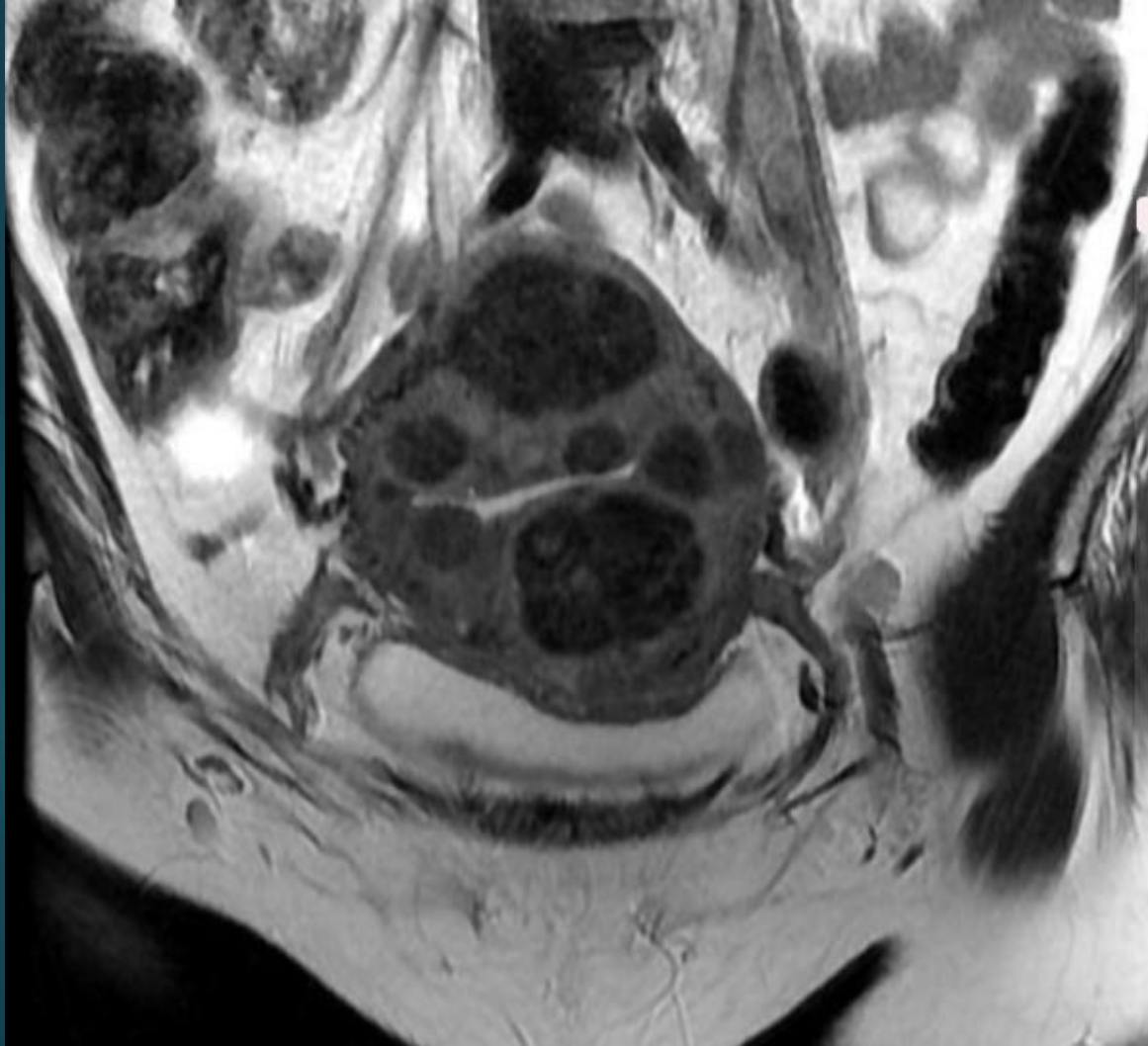7

Subserosal pedunculated

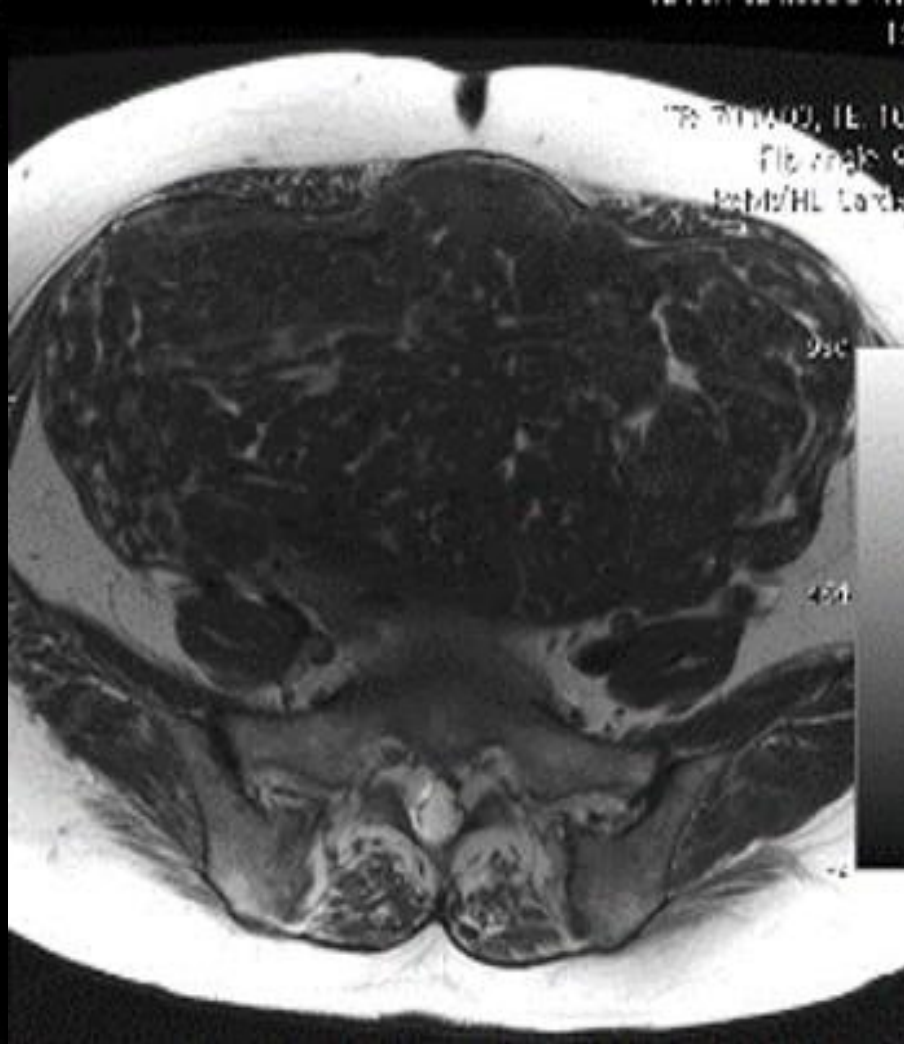
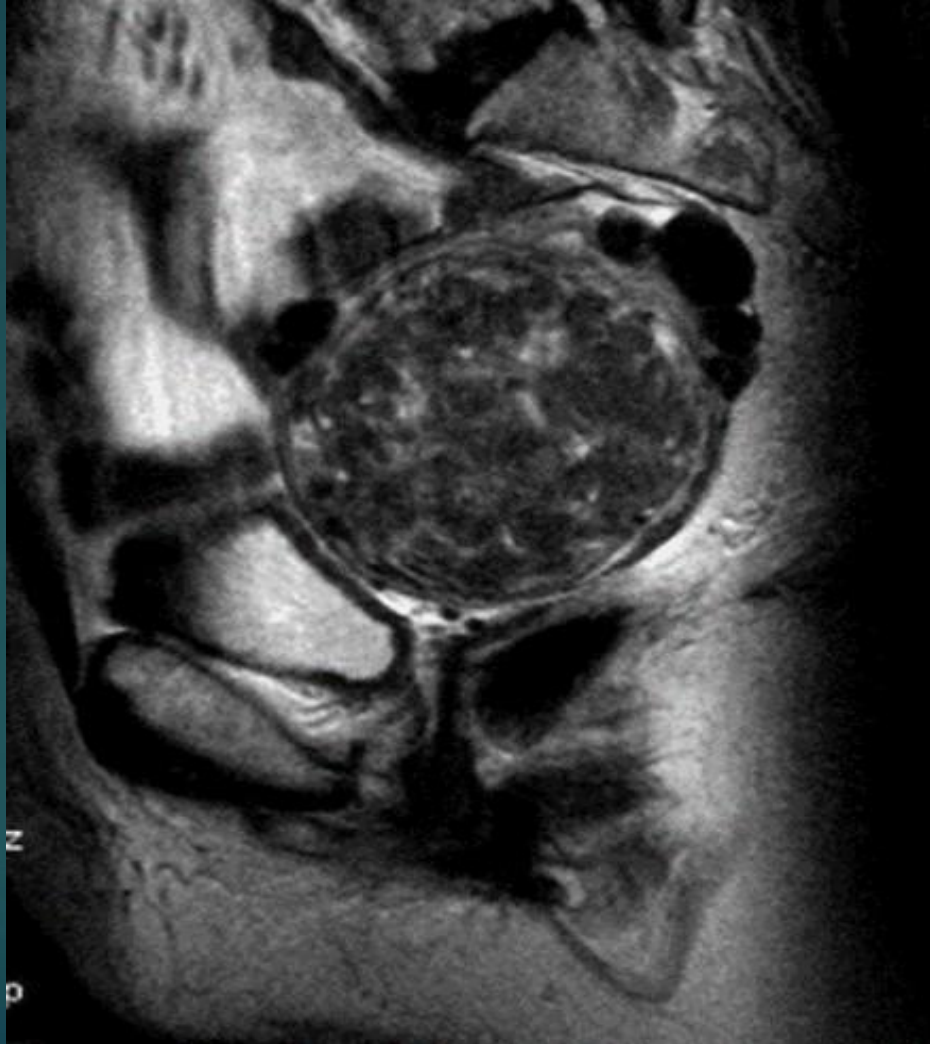2 - 5

Submucosal, subserosal, and $\geq 50\%$ intramural

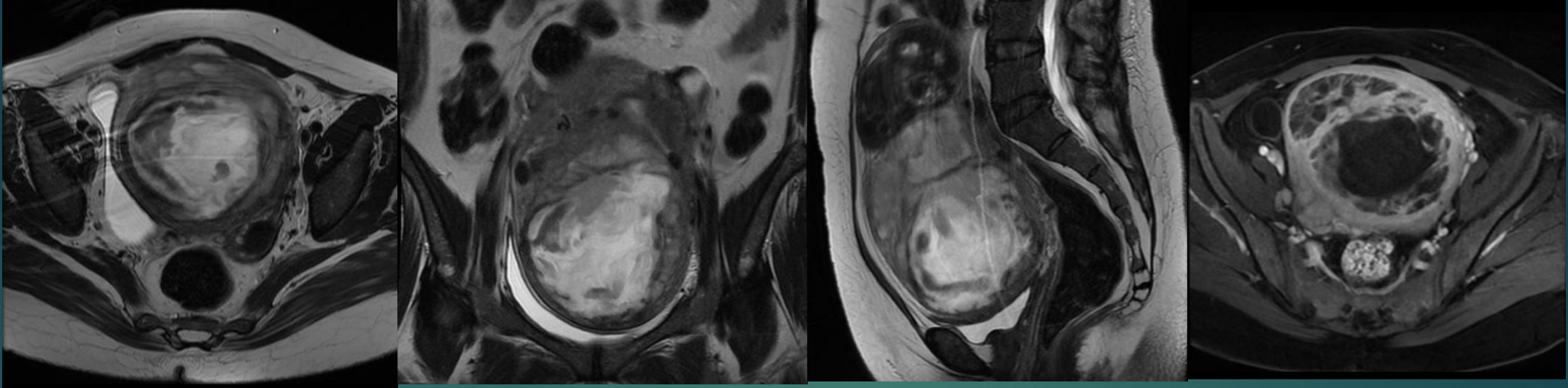




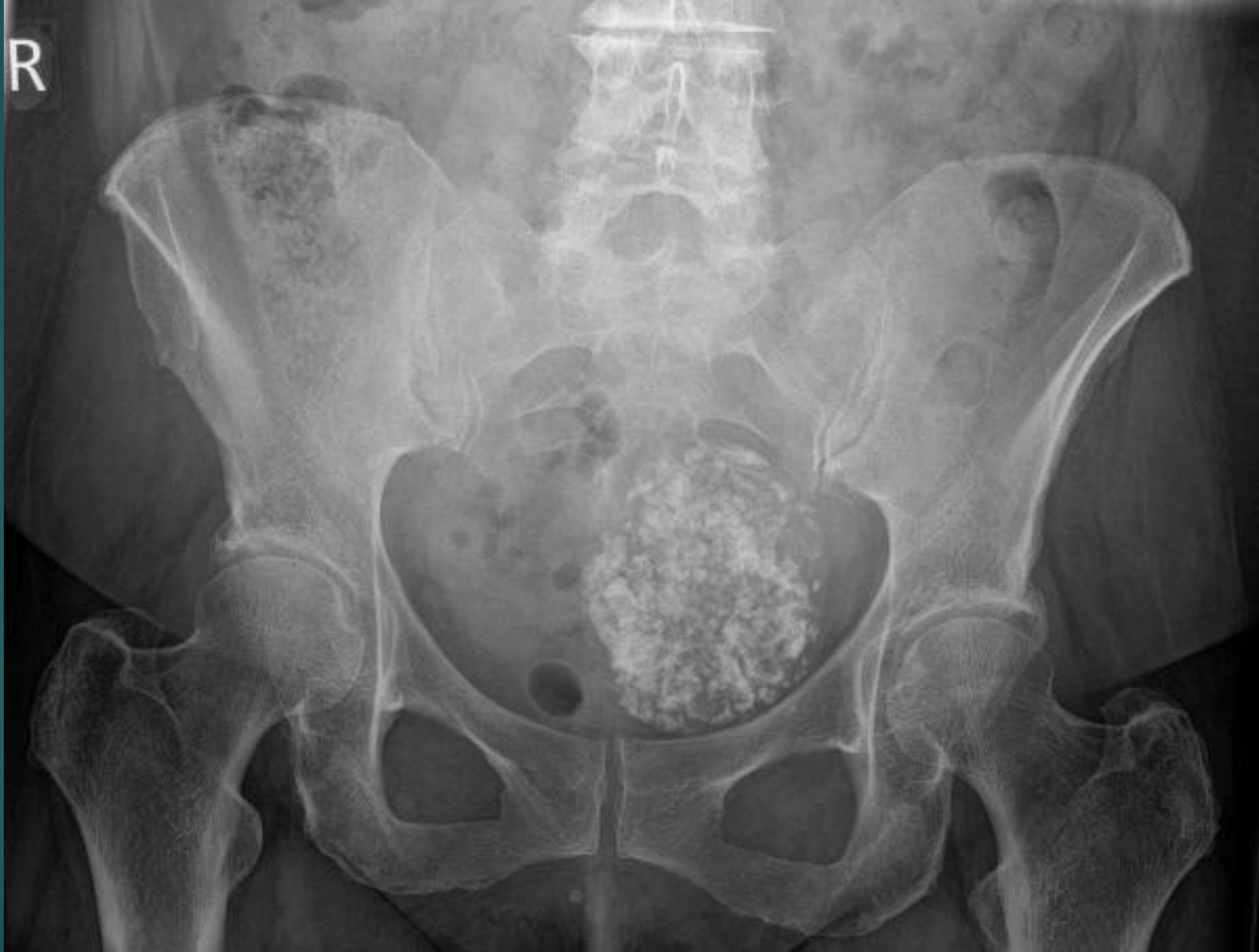HYALİN DEJENERASYON



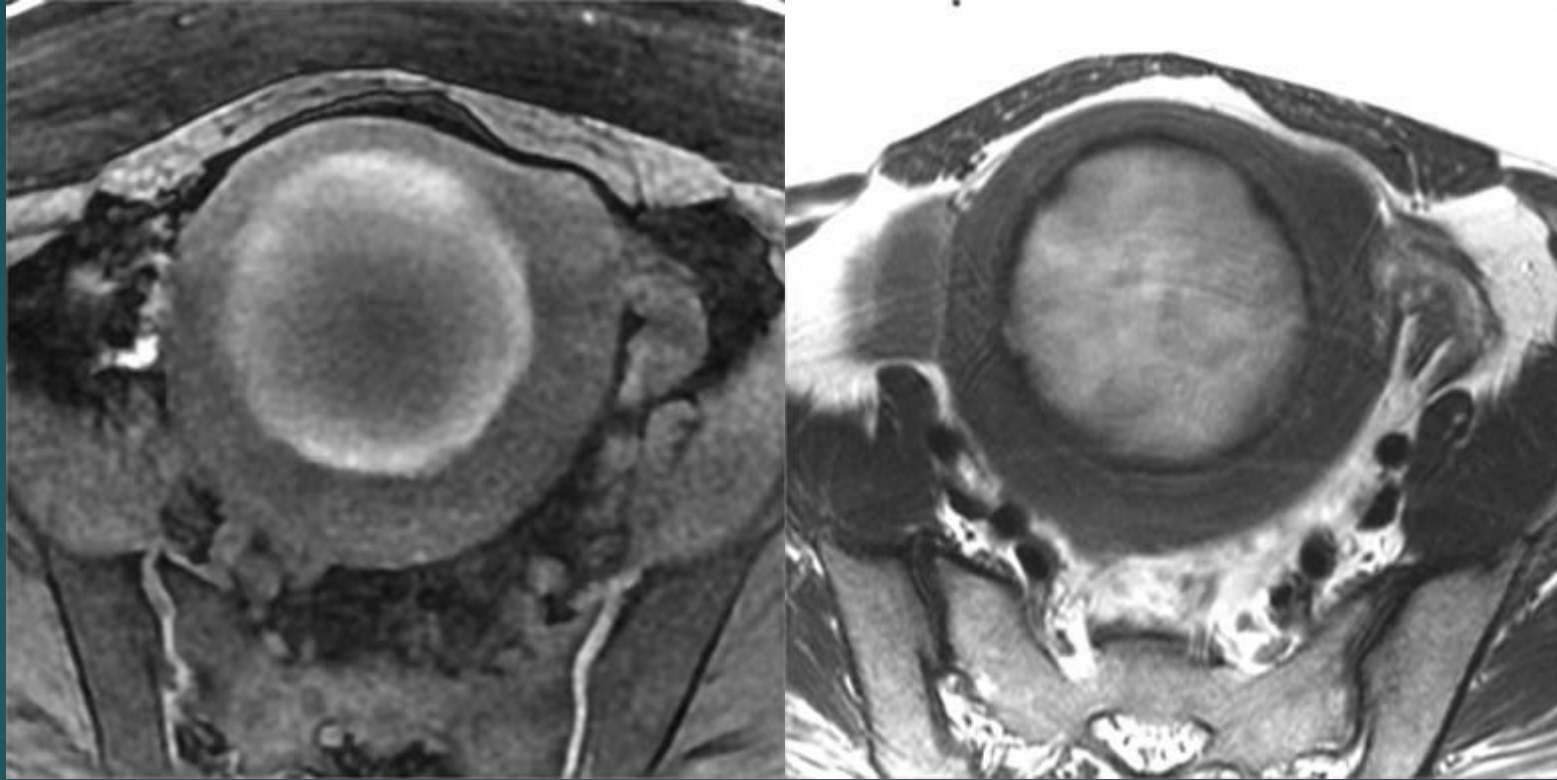
KİSTİK DEJENERASYON



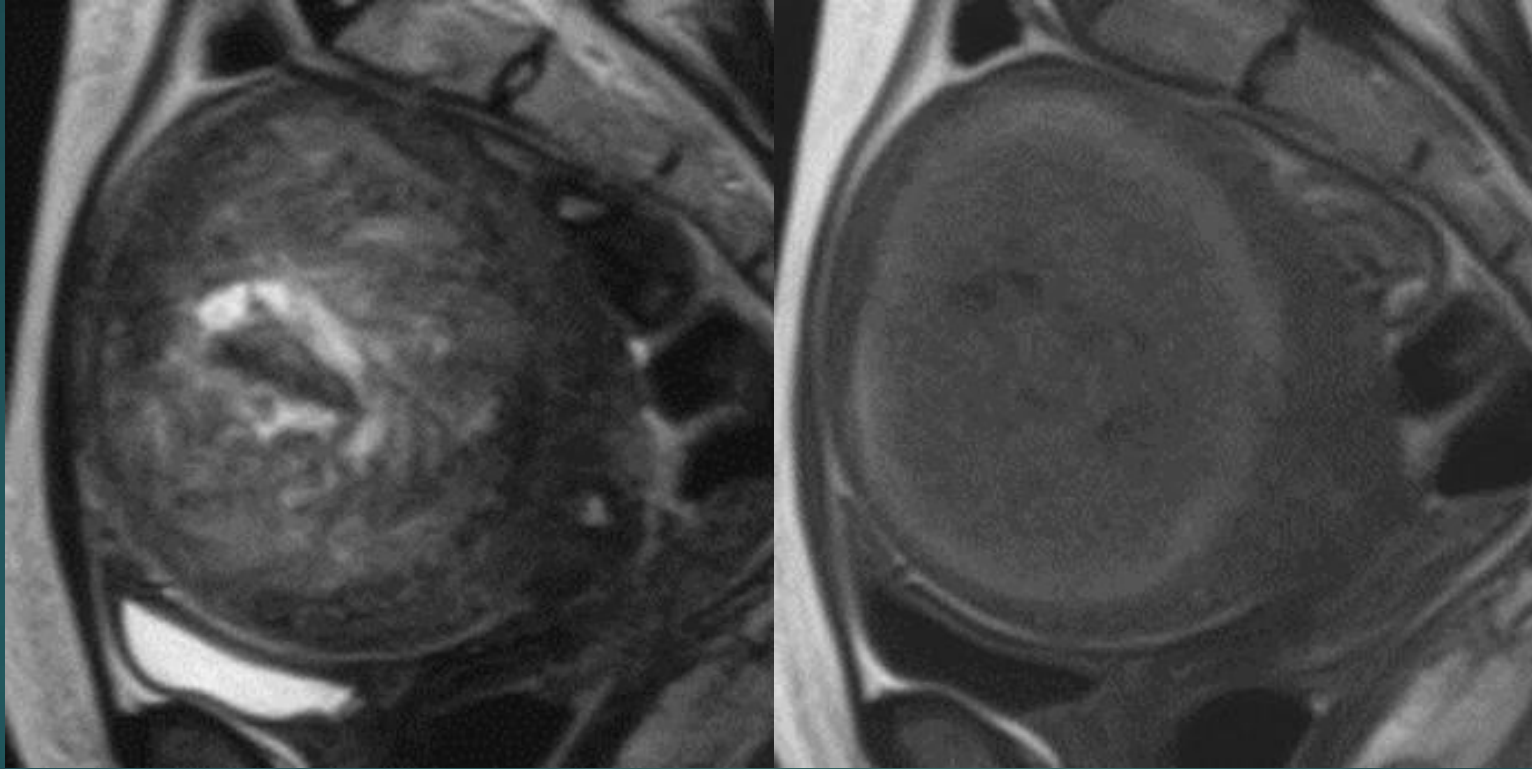
KALSİFİK DEJENERASYON

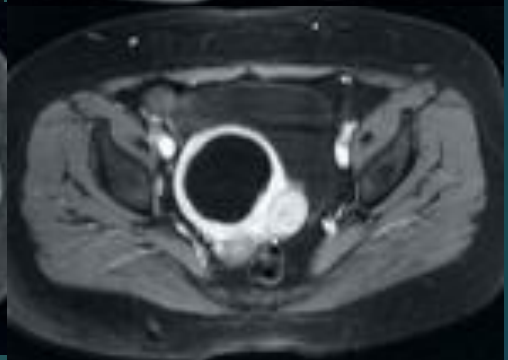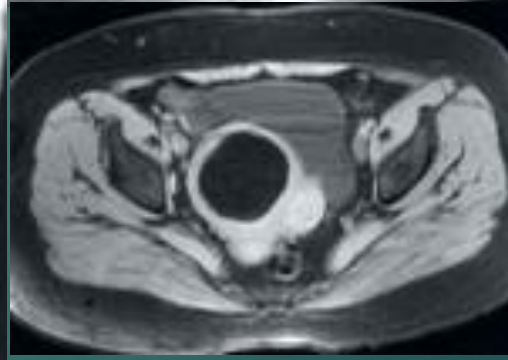
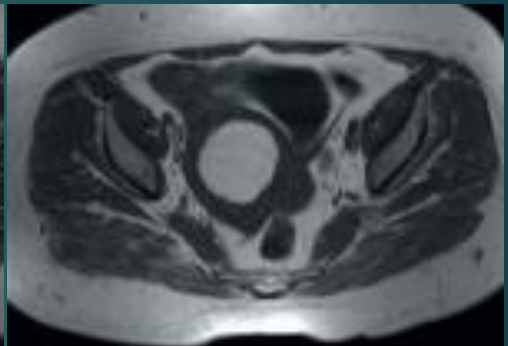
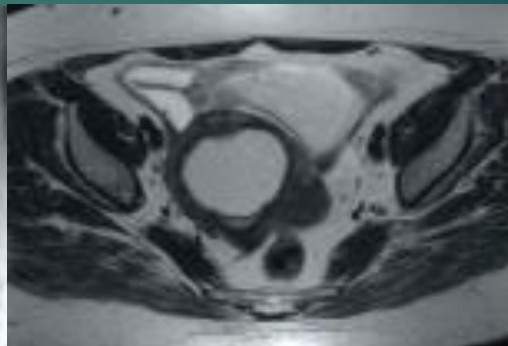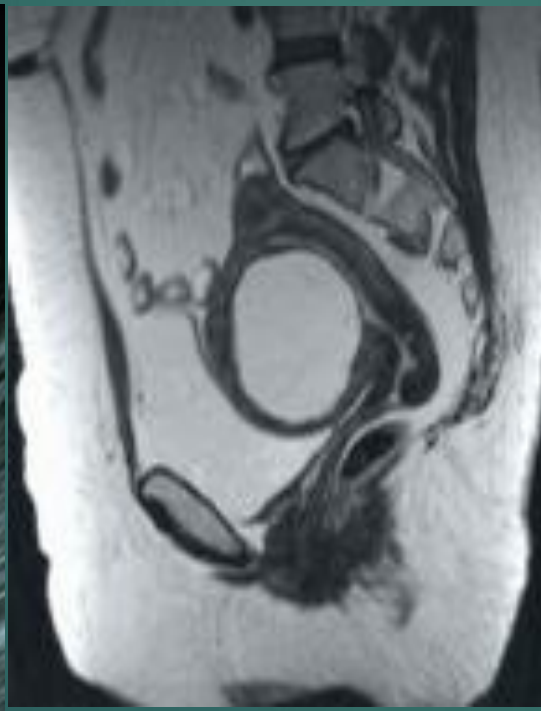
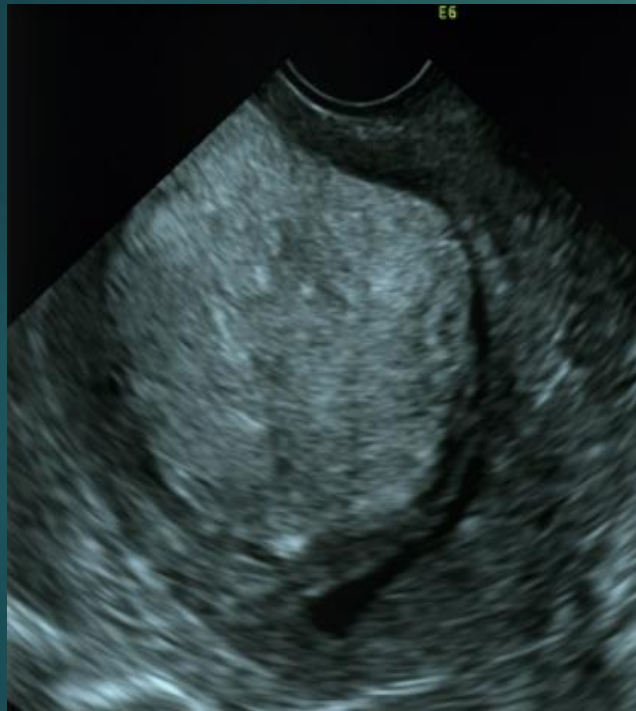


KIRMIZI DEJENERASYON

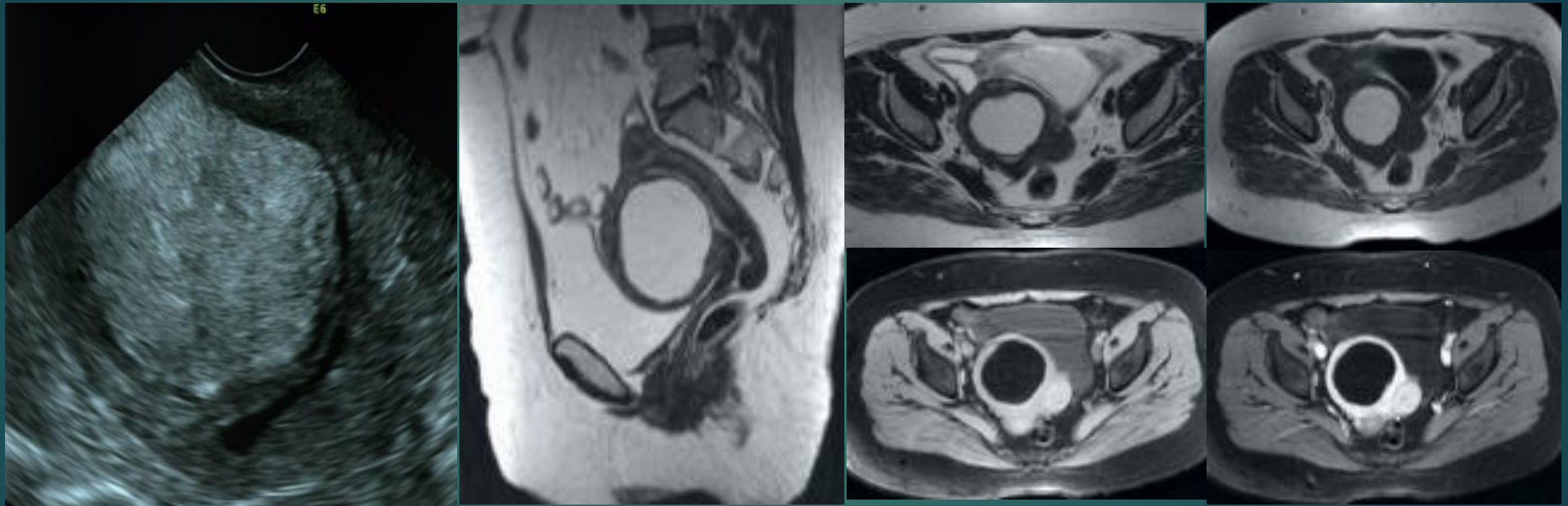


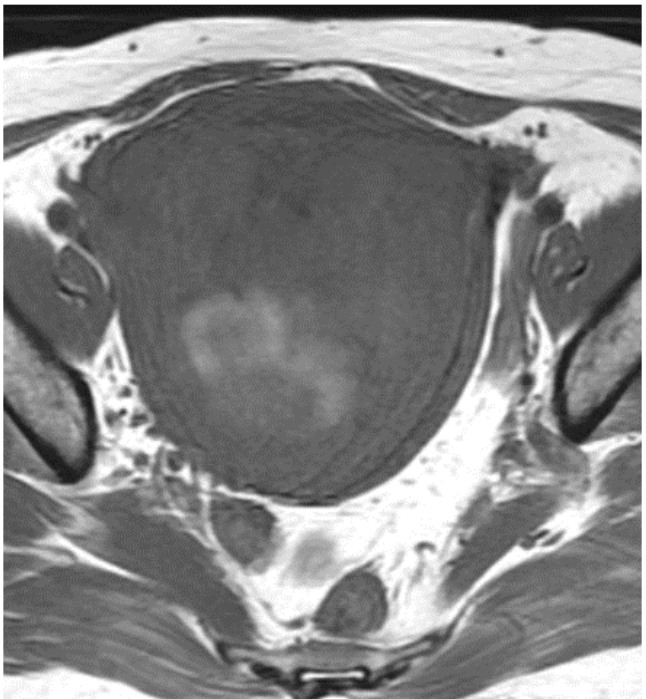
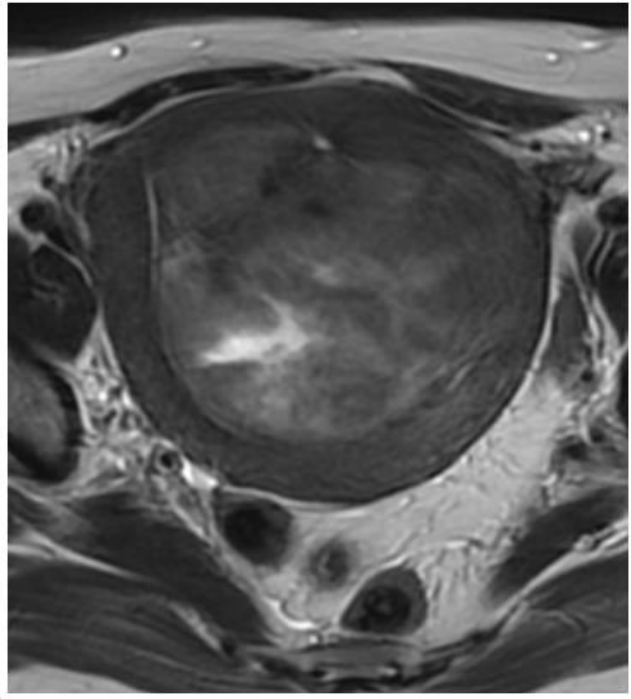
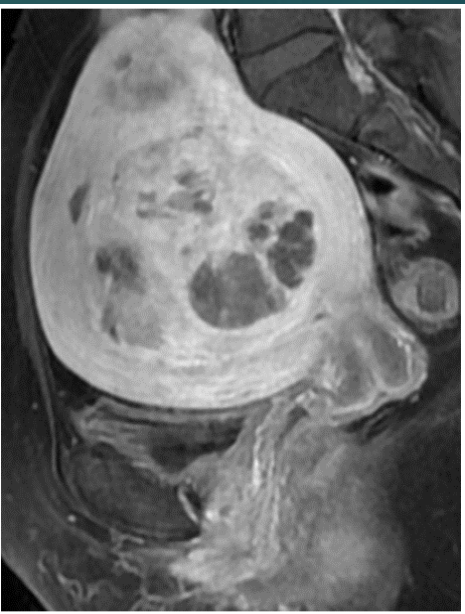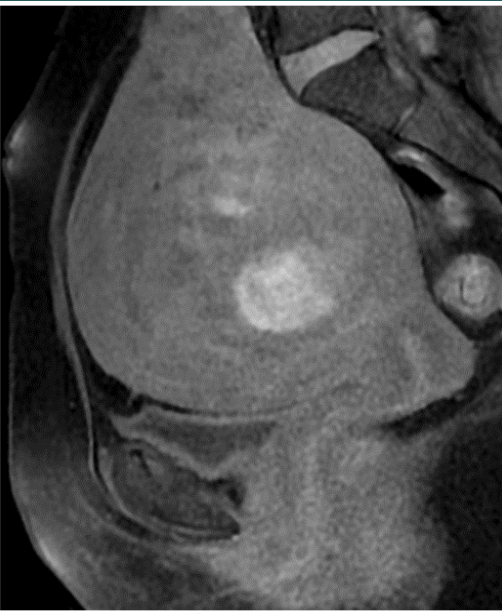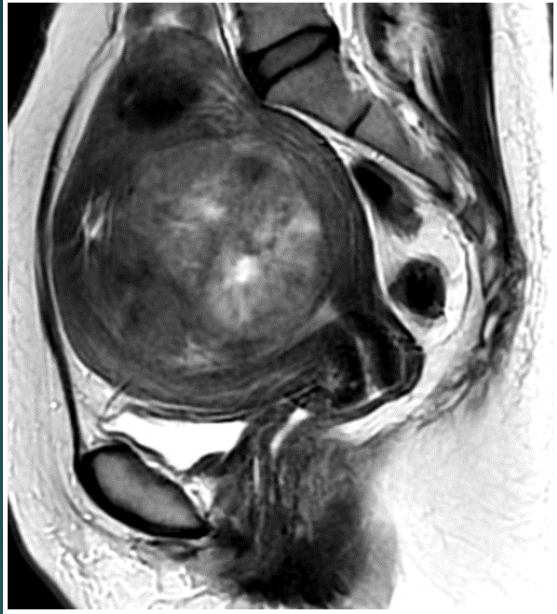KIRMIZI DEJENERASYON

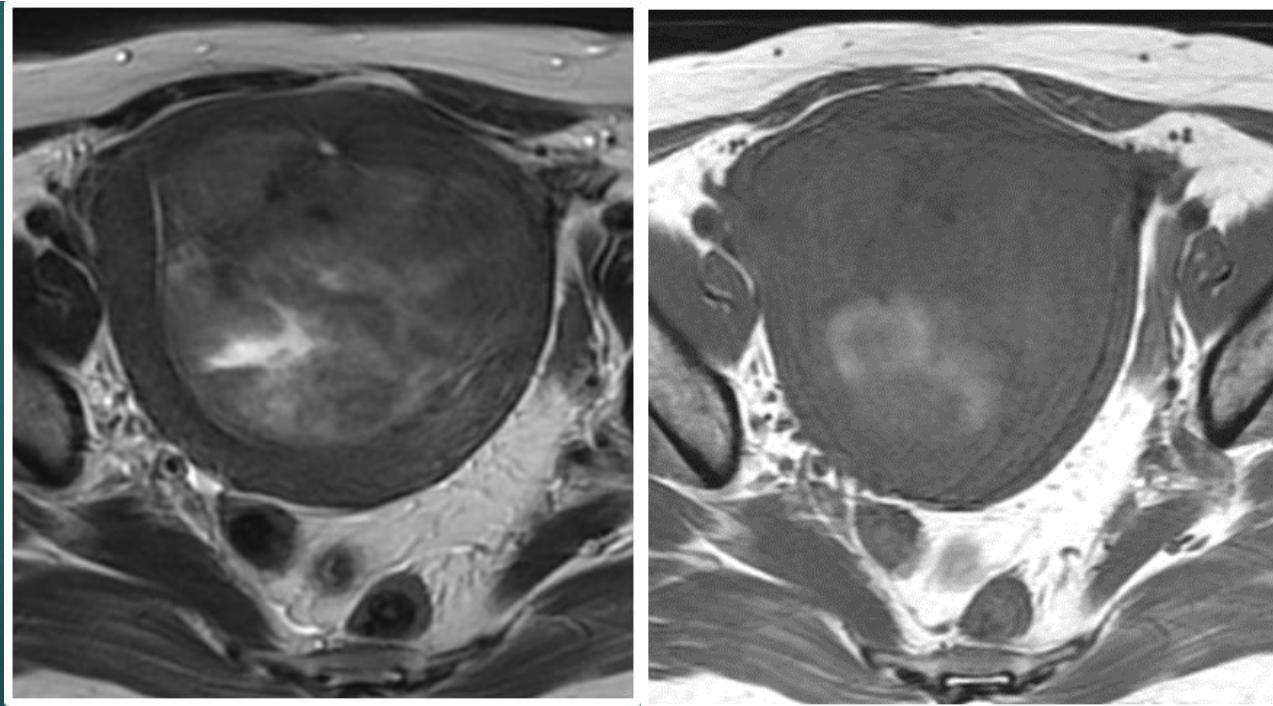
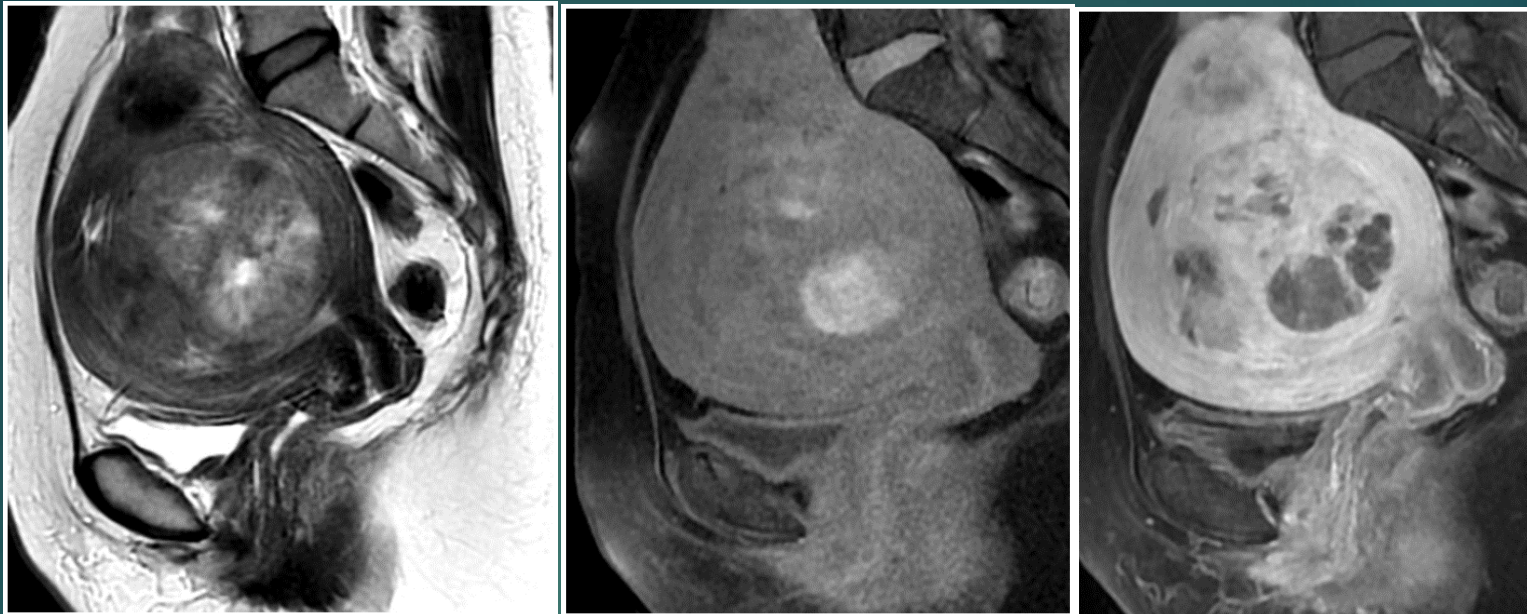



Lipoleiomyom



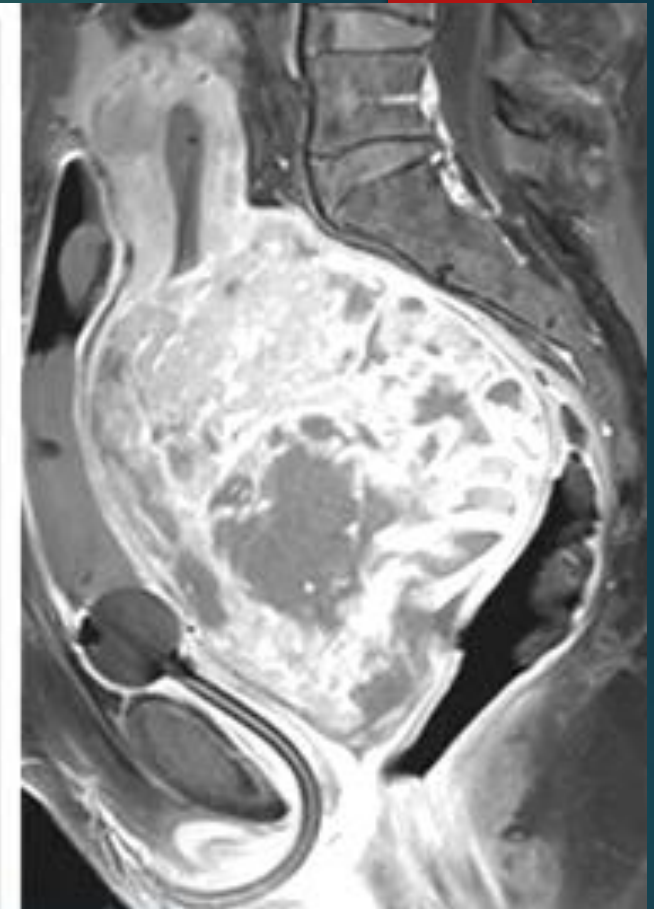
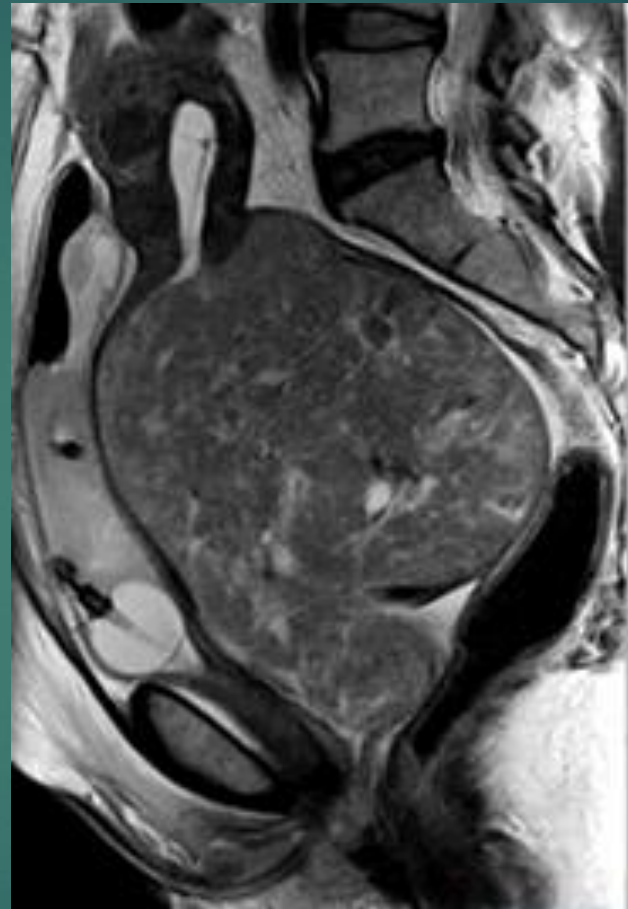


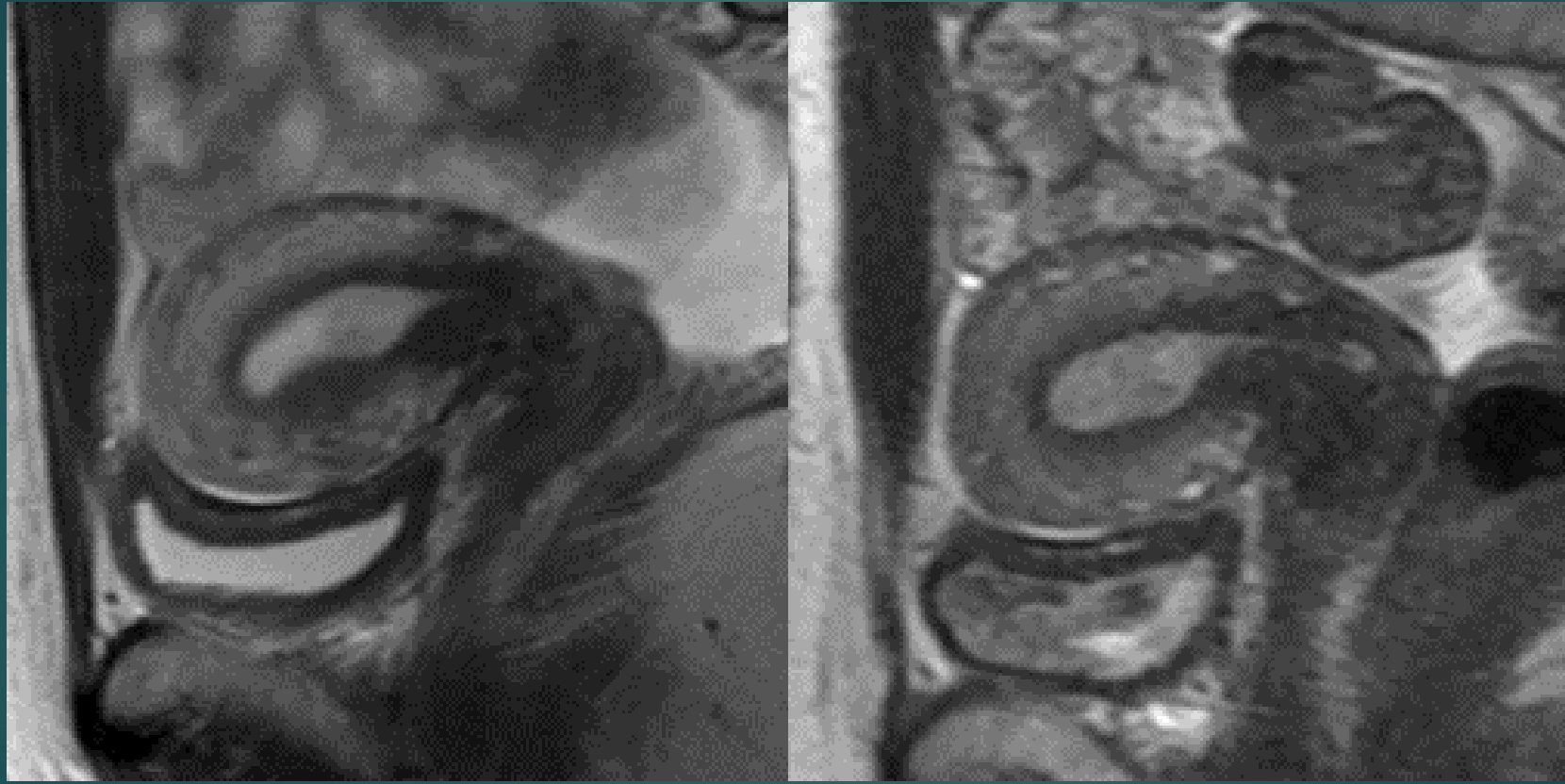


LEIOMYOSARKOM

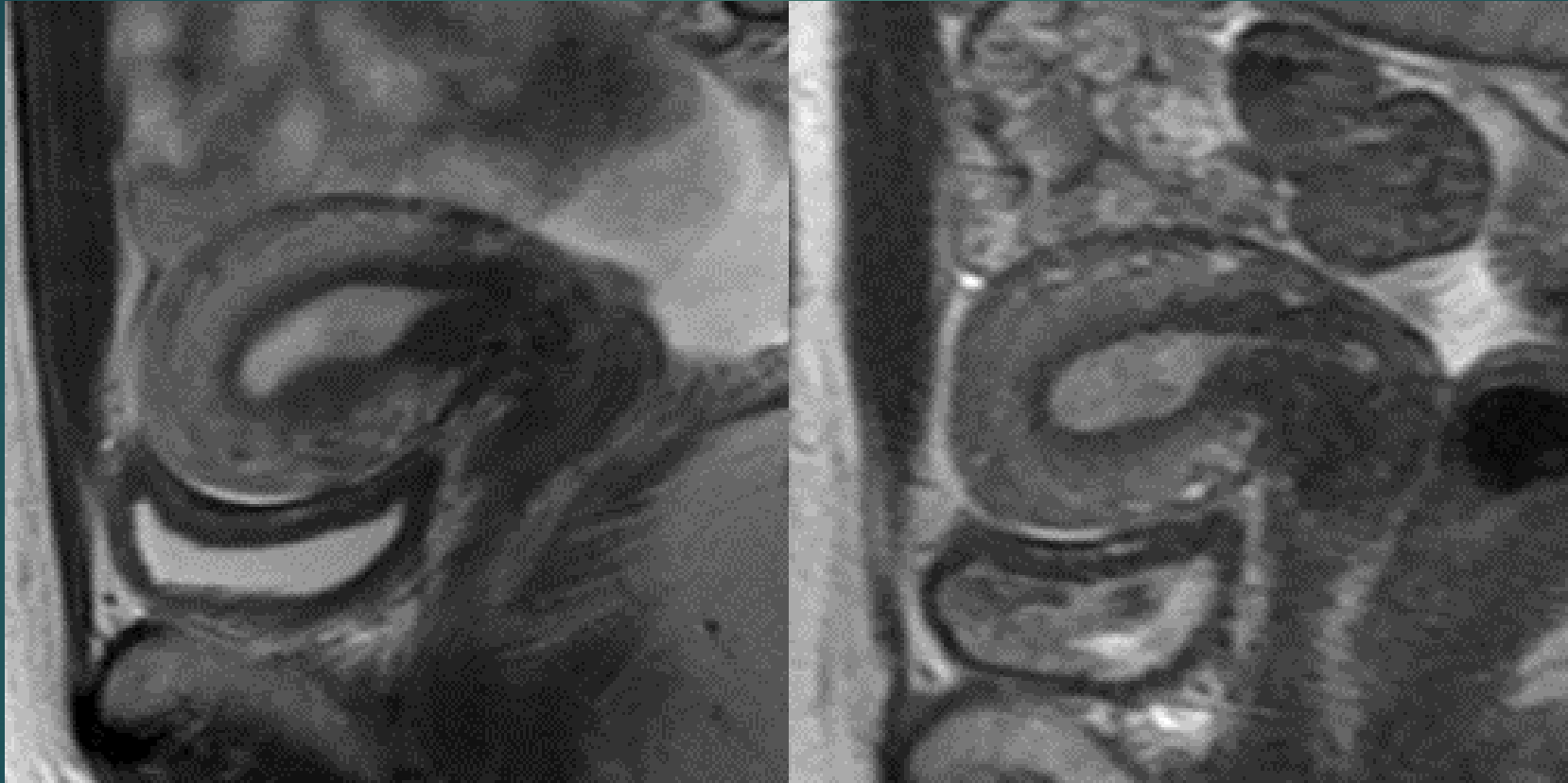
	Leiomyoma	Leiomyosarcoma
Age	Premenopausal	Peri/postmenopausal
Borders	Well delineated	Often nodular ^o
DWI	Variable	Restricted diffusion, low ADC
Invasiveness	No	Adjacent tissues
Number	Commonly multiple	Solitary
Size	Variable	Large (>10cm)
T2WI	Mostly low, high in degeneration, whorled pattern	Inhomogenous with areas of hemorrhage ^o , intralesional vessels; T2 dark areas ^o
Vascularity	Variable: often parallels myometrium, cellular types with avid enhancement	Hypervascularization: peripheral early enhancement, central necrosis ⁺

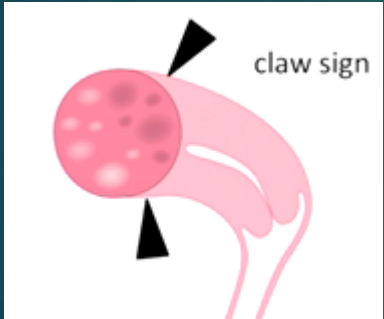
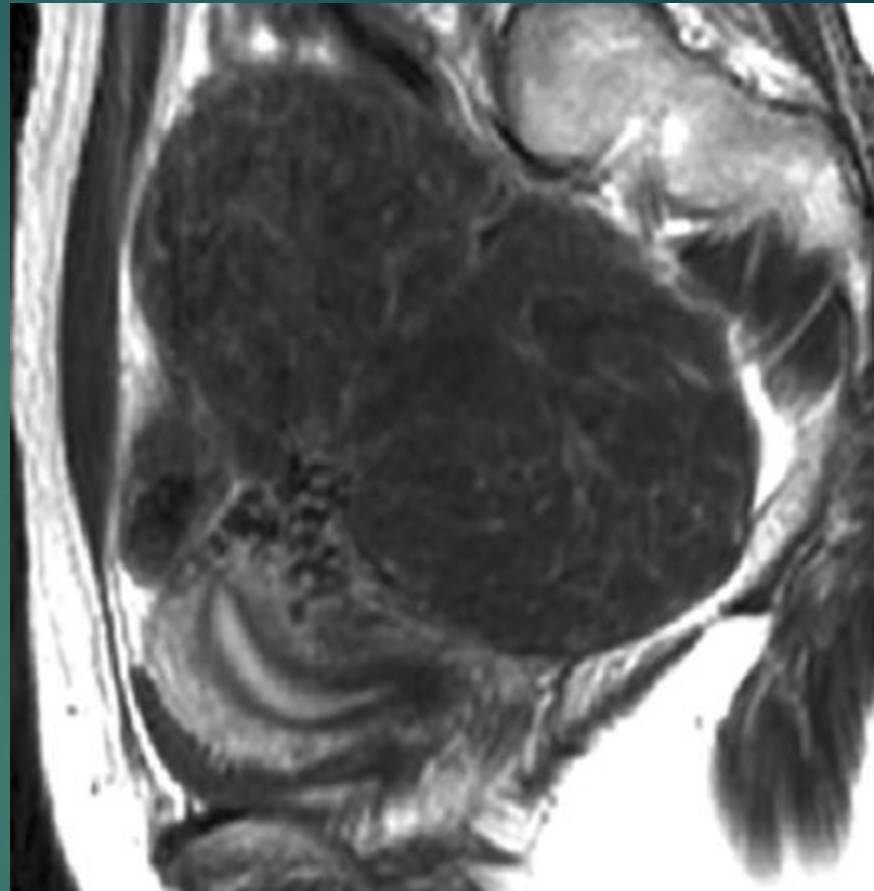
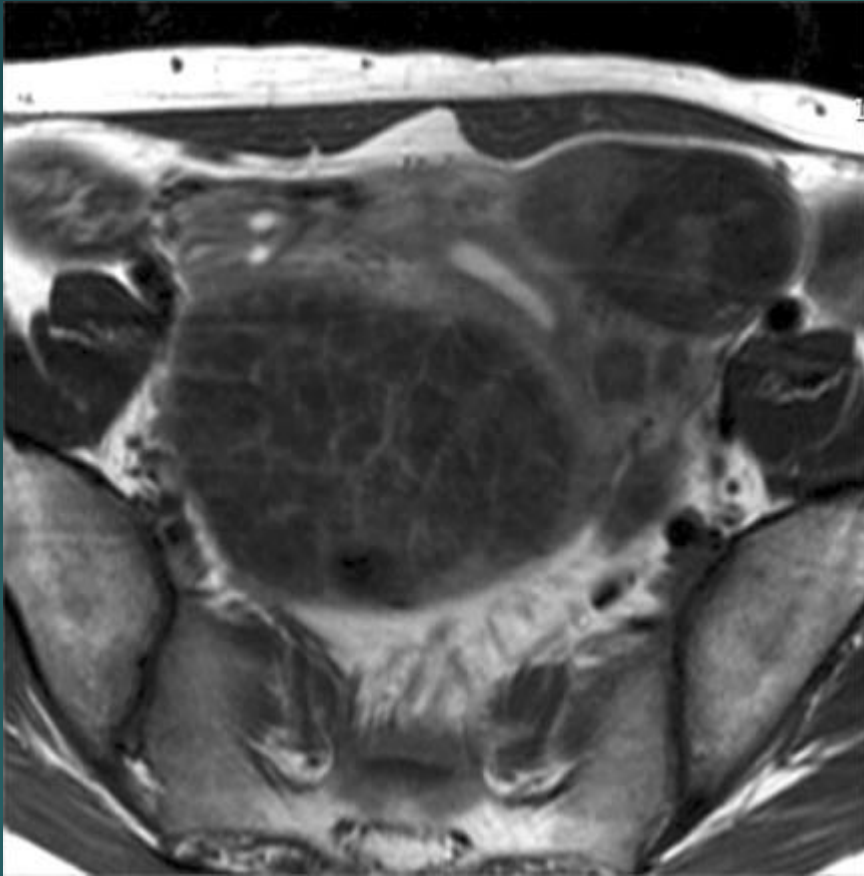
^o ≥3 of ^o features: 95% specificity in predicting leiomyosarcoma according to Lakhman and al (features are highlighted in bold) (26)



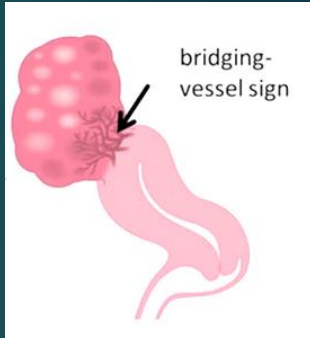


TRANSİENT MYOMETRİAL KONTRAKSİYON





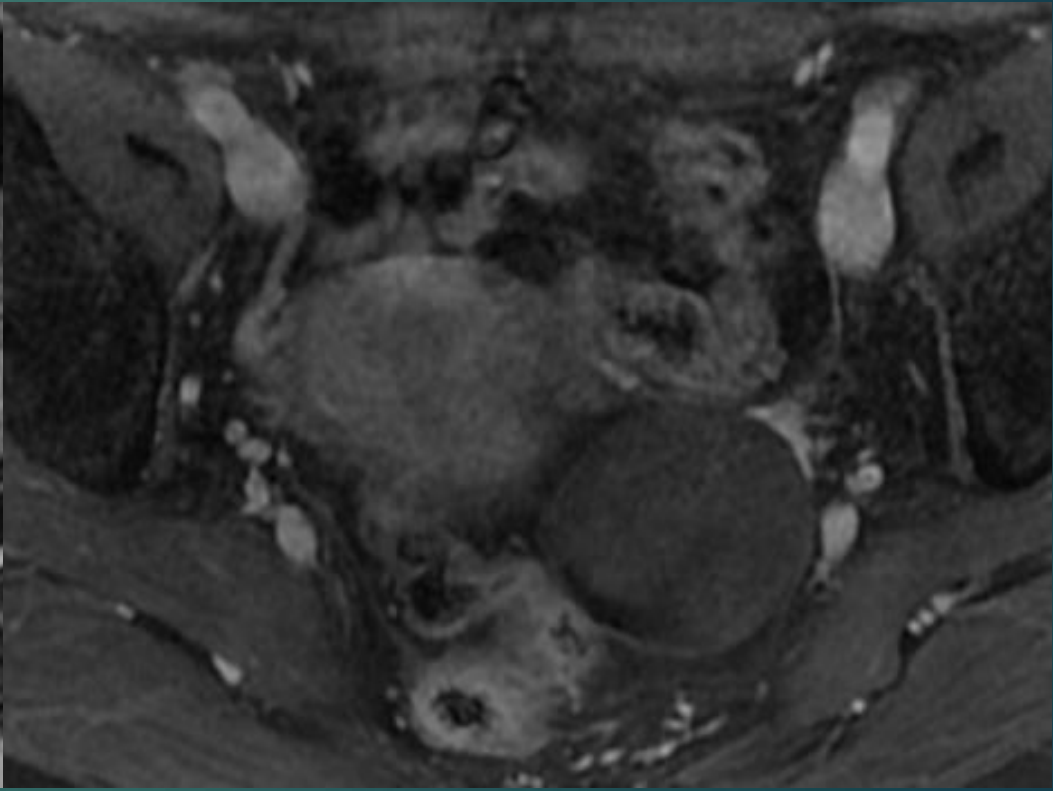
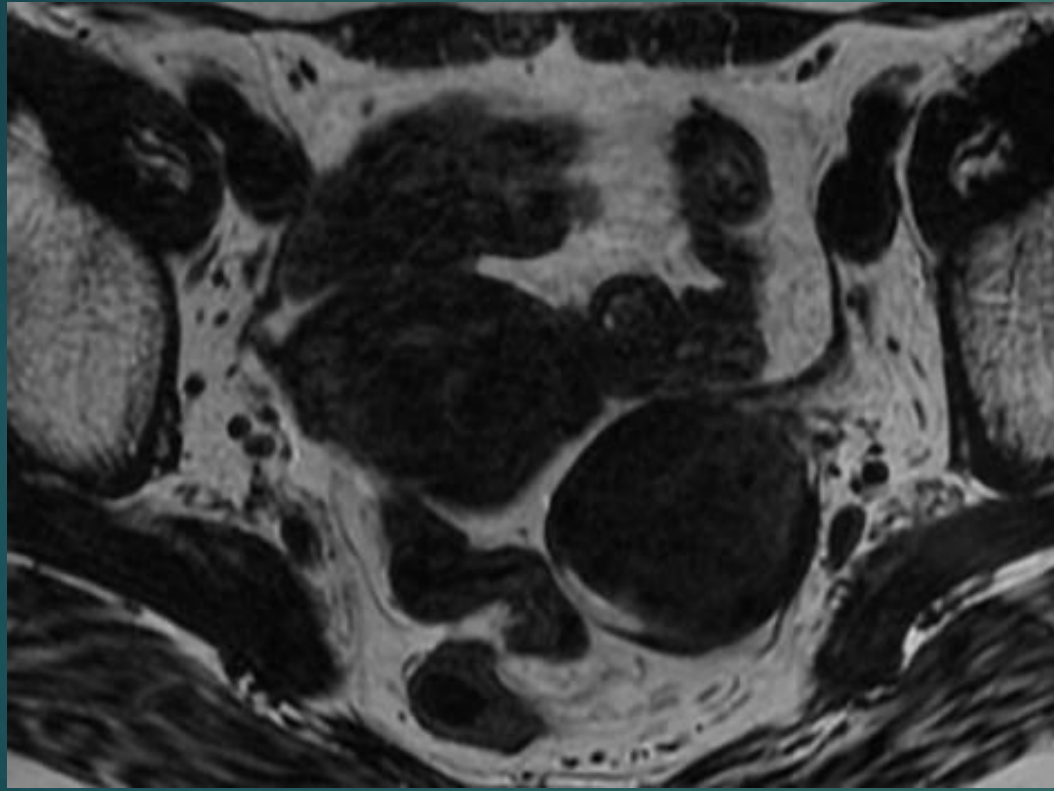
claw sign



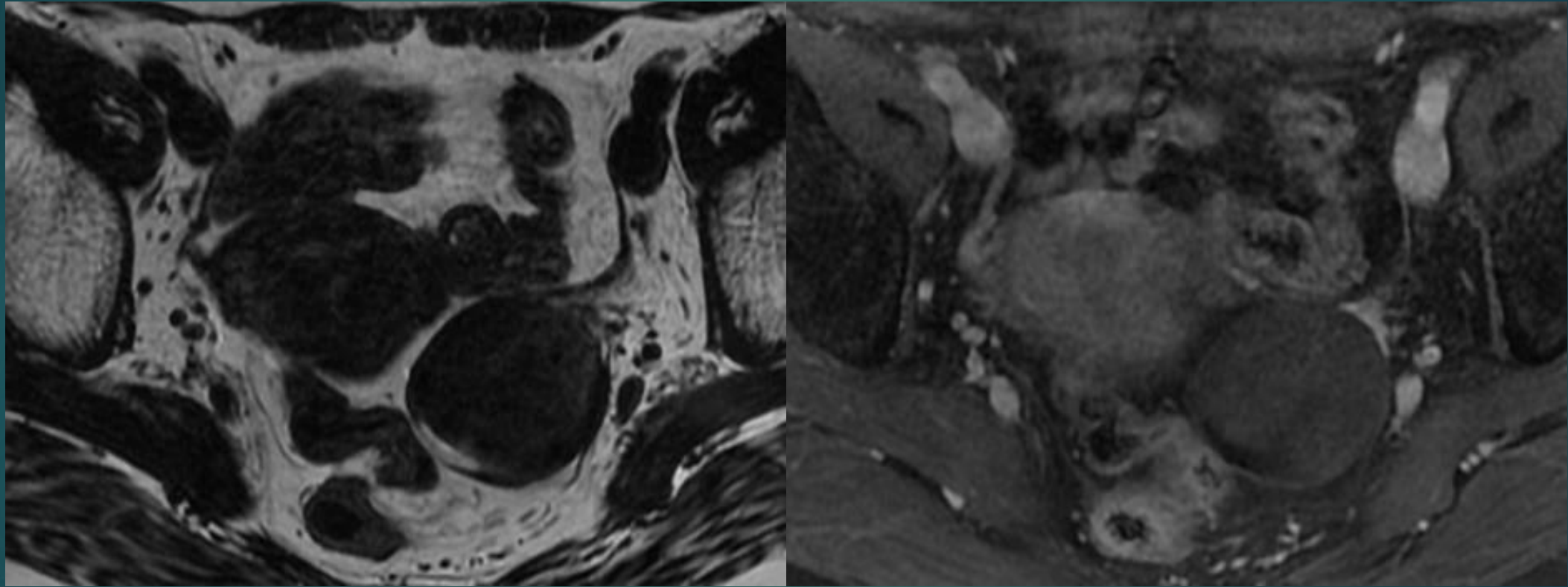
bridging-vessel sign

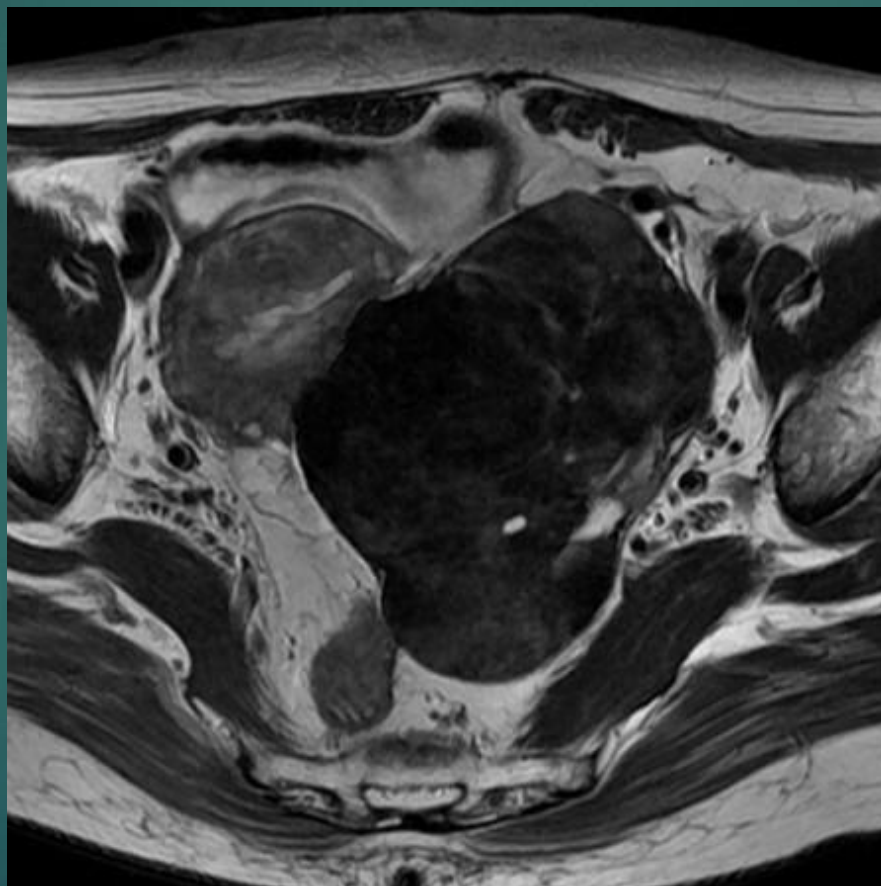
CLAW SIGN

BRIDGING VESSEL SIGN

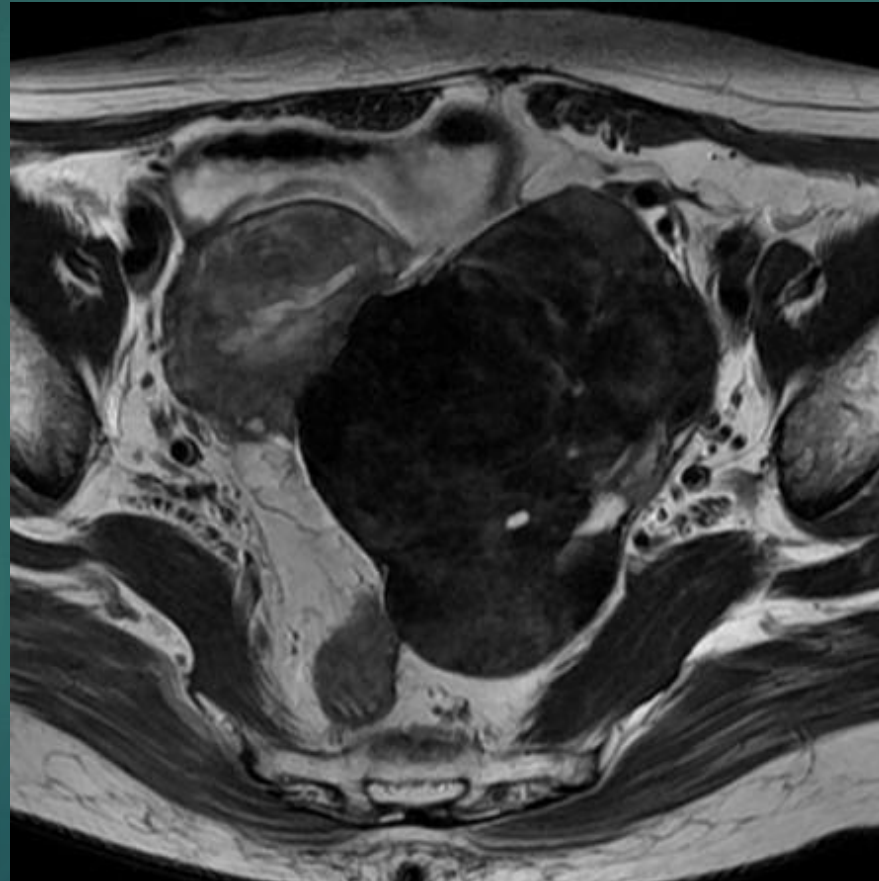


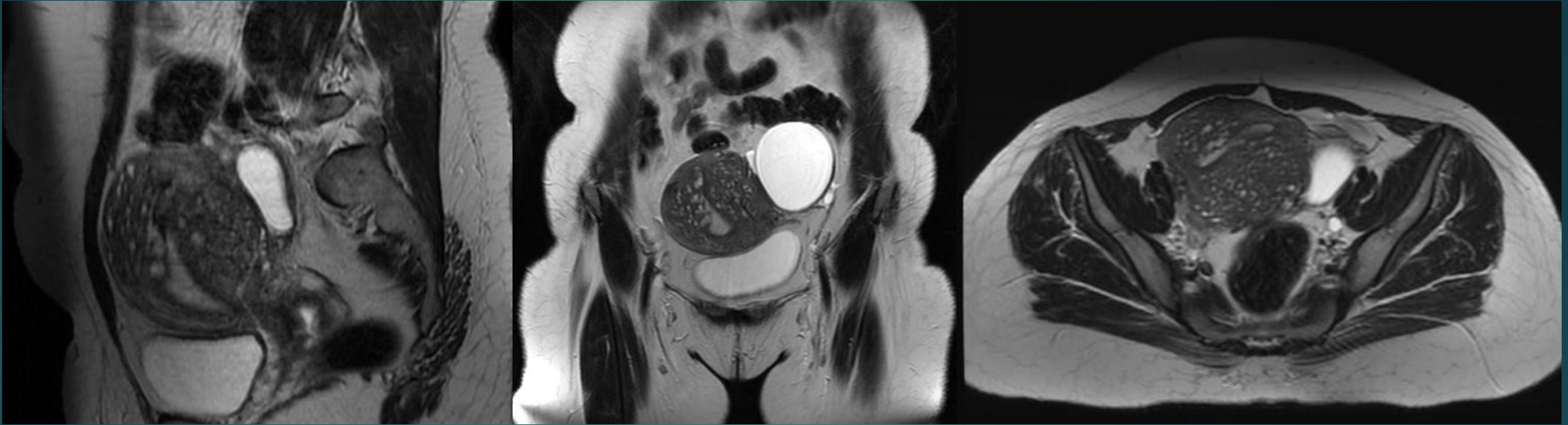
OVARYAN FIBROM



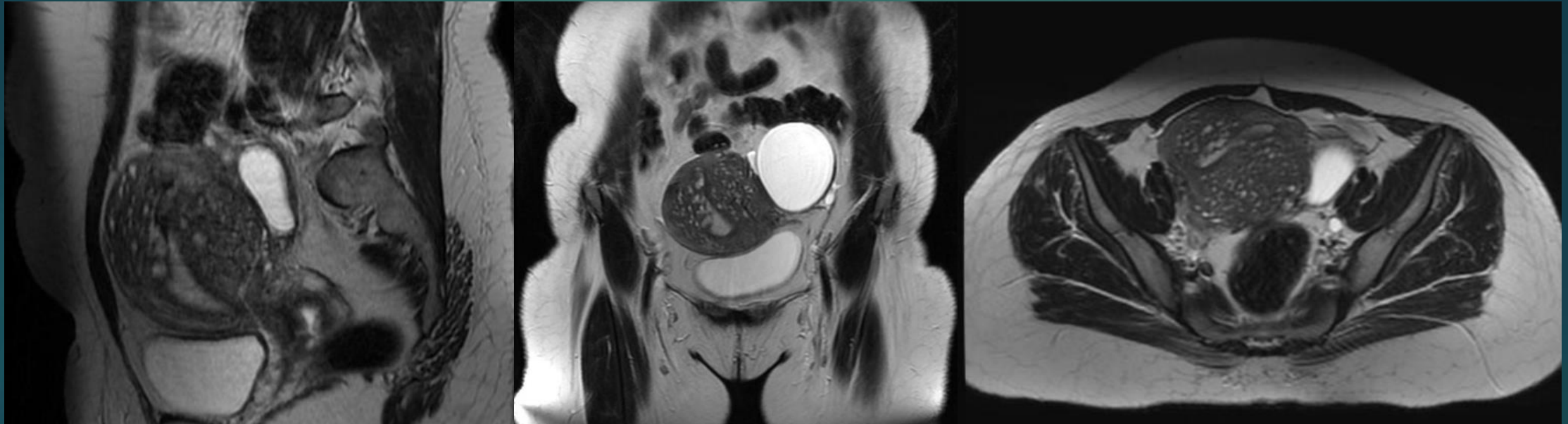


BRENNER TÜMÖR



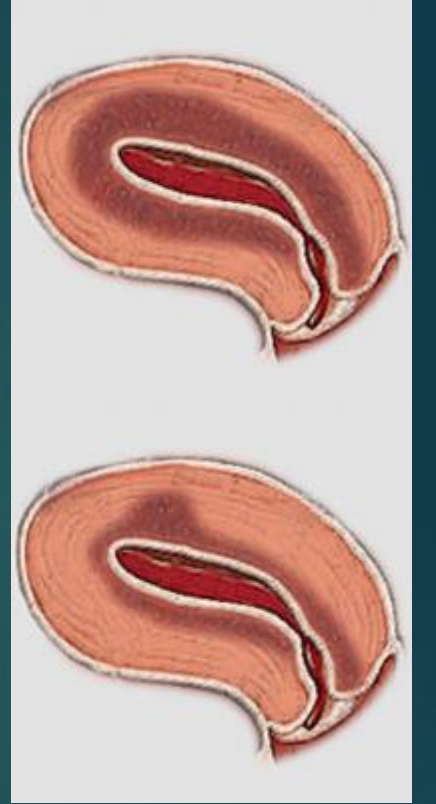



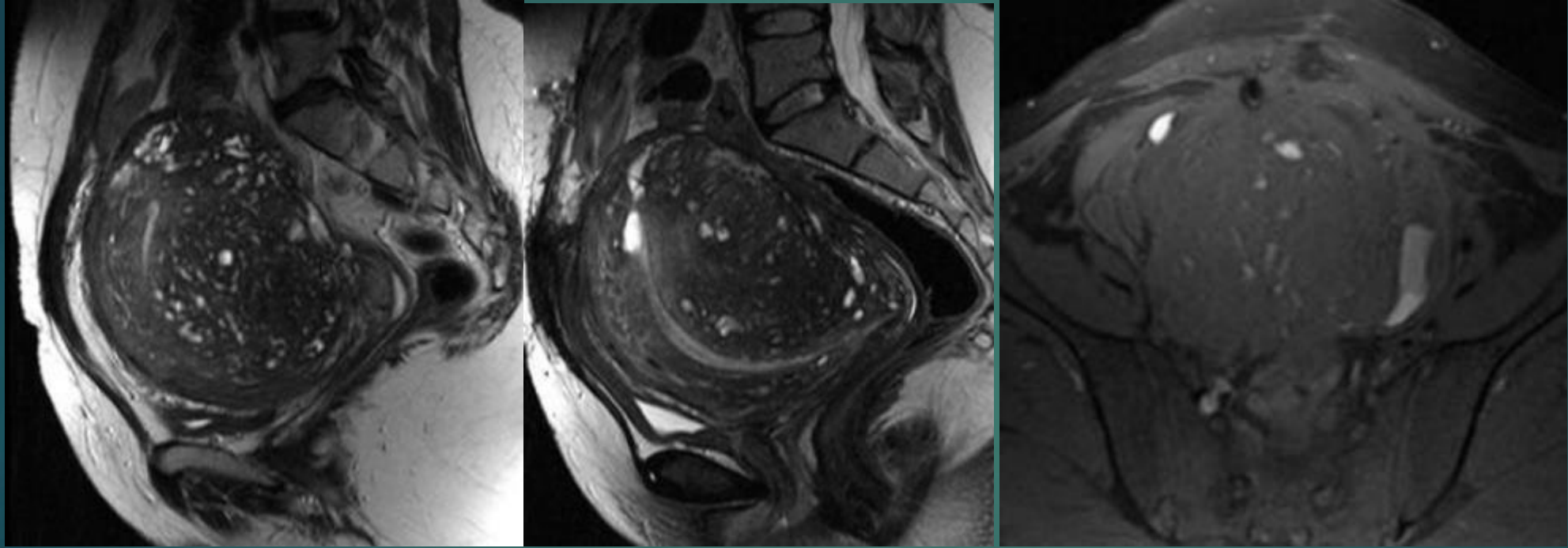
ADENOMYOSIS



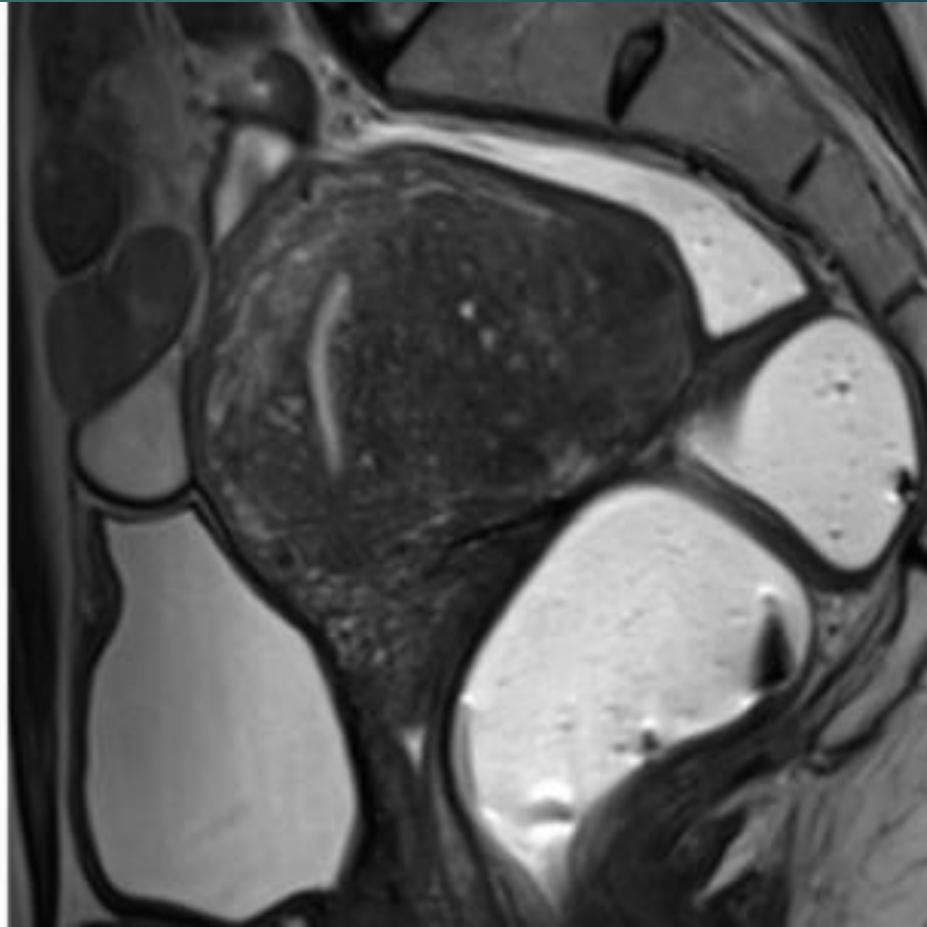
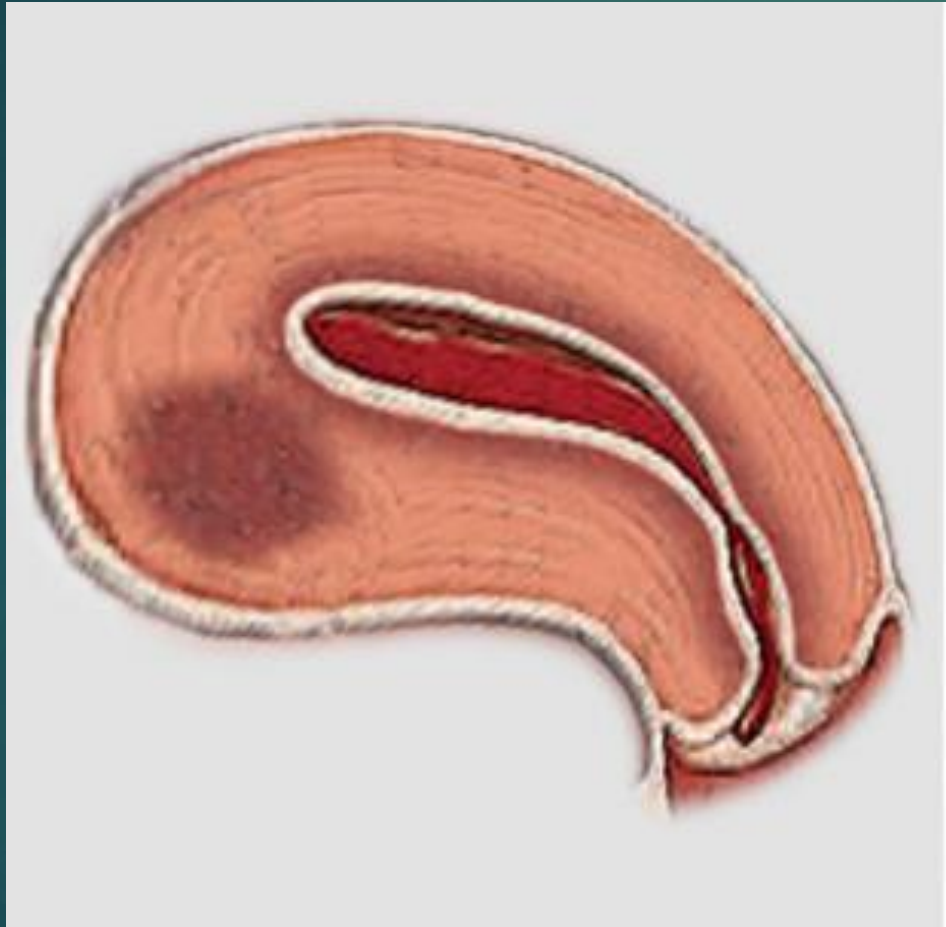
ADENOMYOZİS

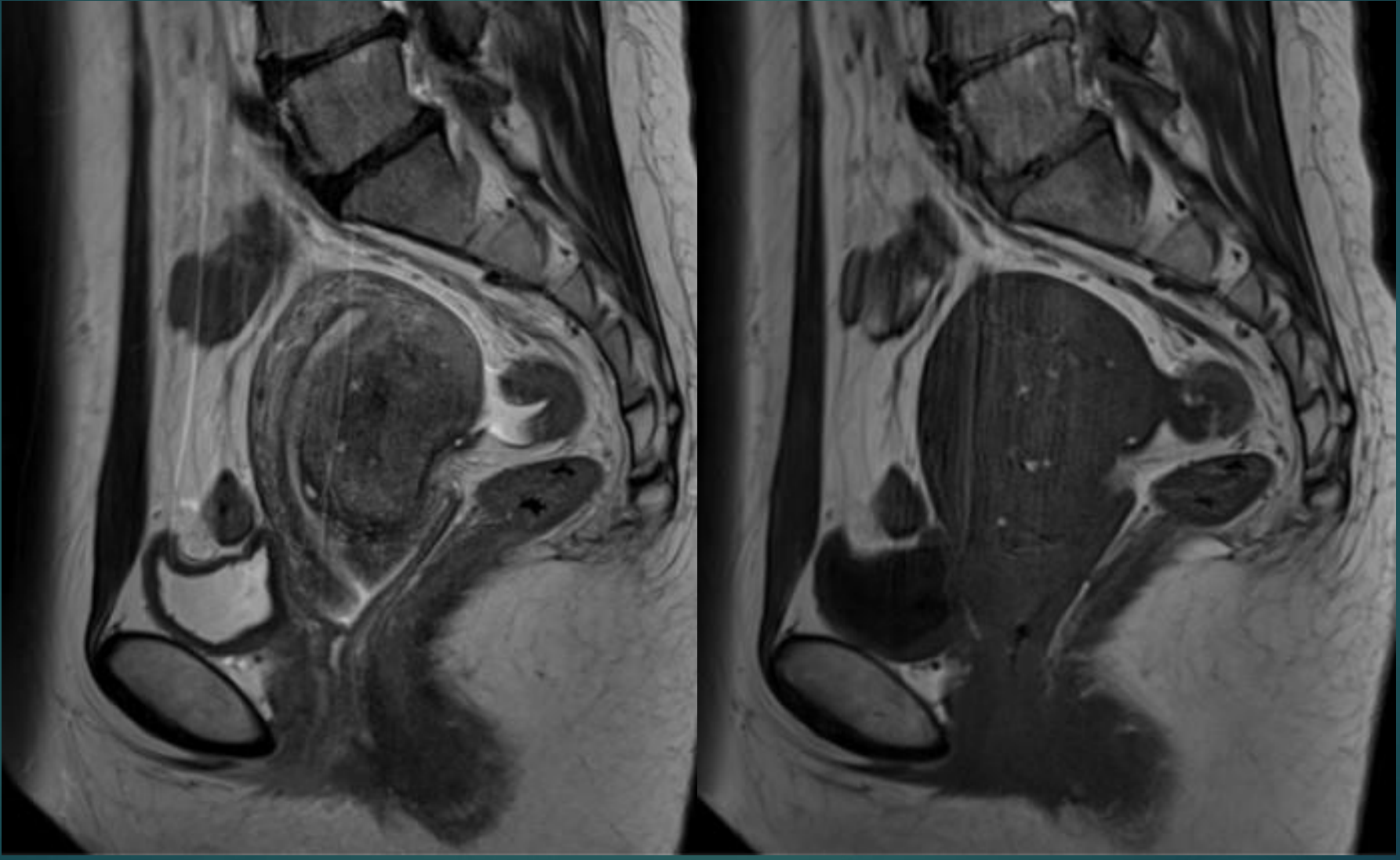
- ▶ Ektopik endometrial dokunun myometriuma invazyonu
- ▶ Multiparite
- ▶ Endometriozis(%20) ve myom(%50) ile birliktelik.
- ▶ Fokal(adenomyoma),diffüz,kistik(adenomyotik kist)
- ▶ Junctional zonda >12 mm kalınlaşma ve içerisinde milimetrik hemorajik odaklar.



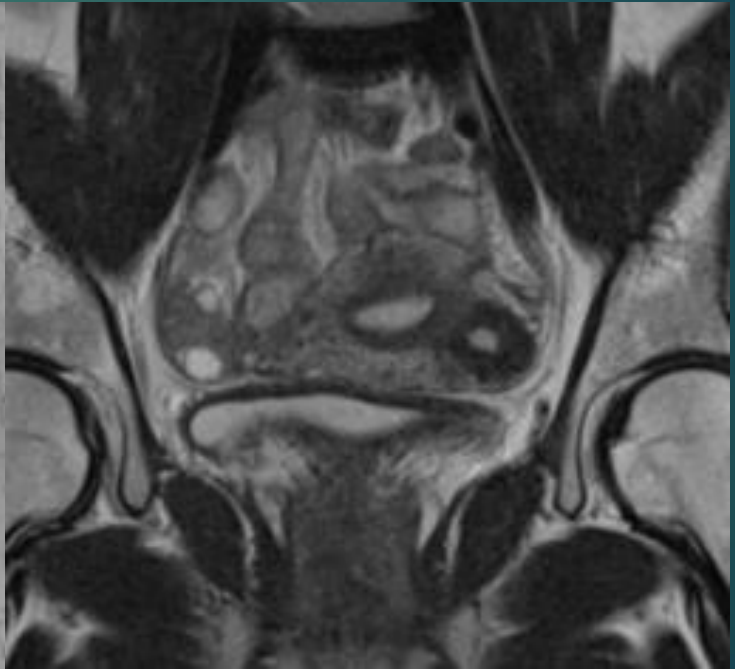
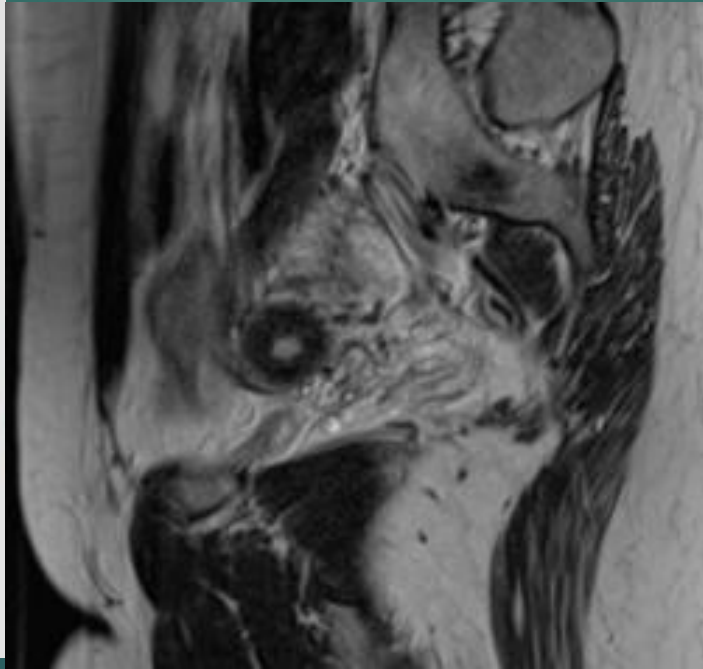
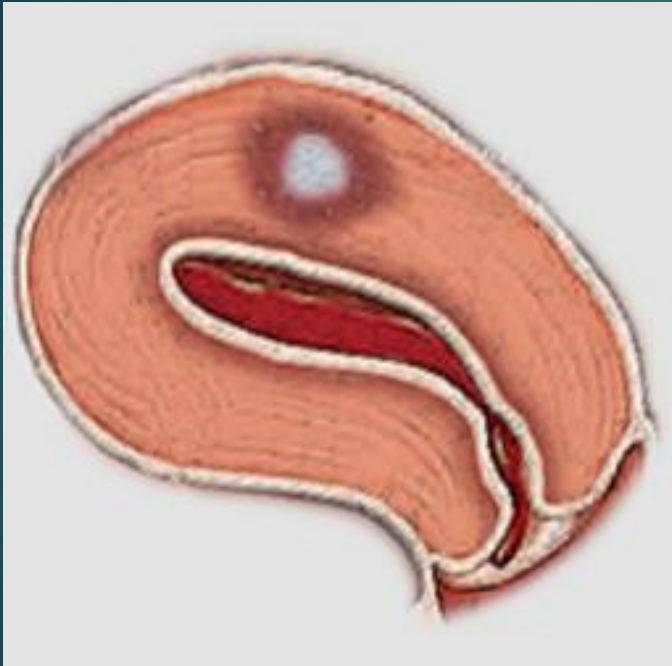

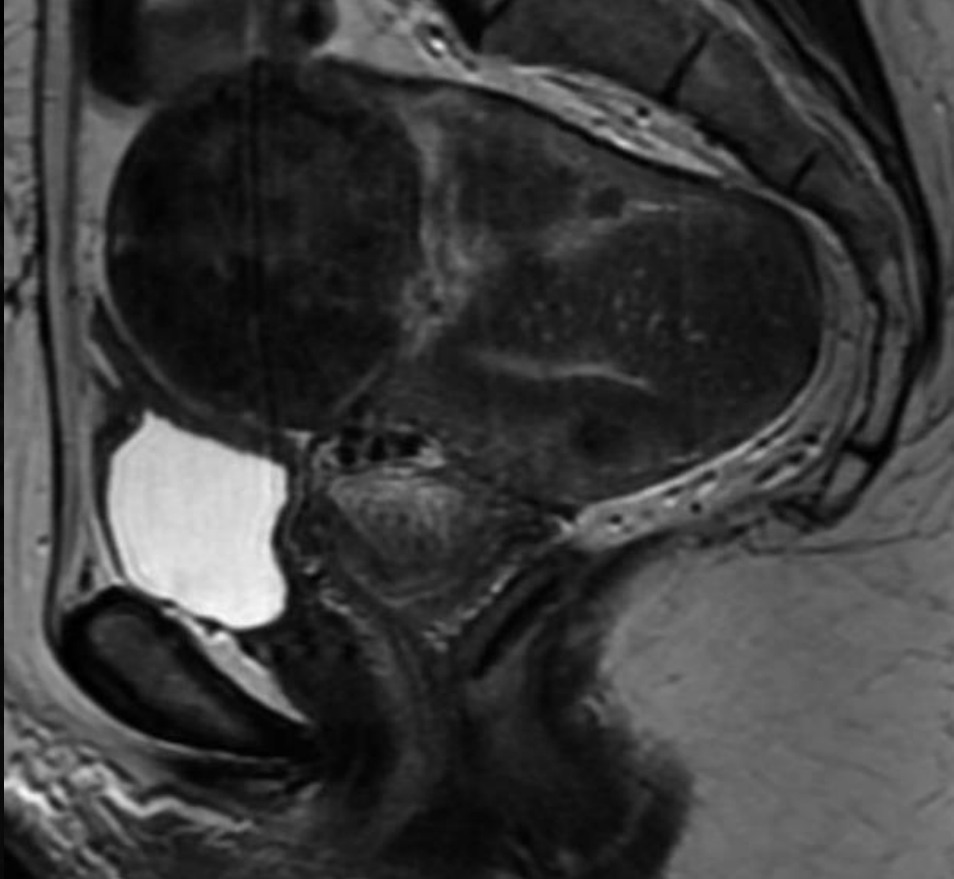
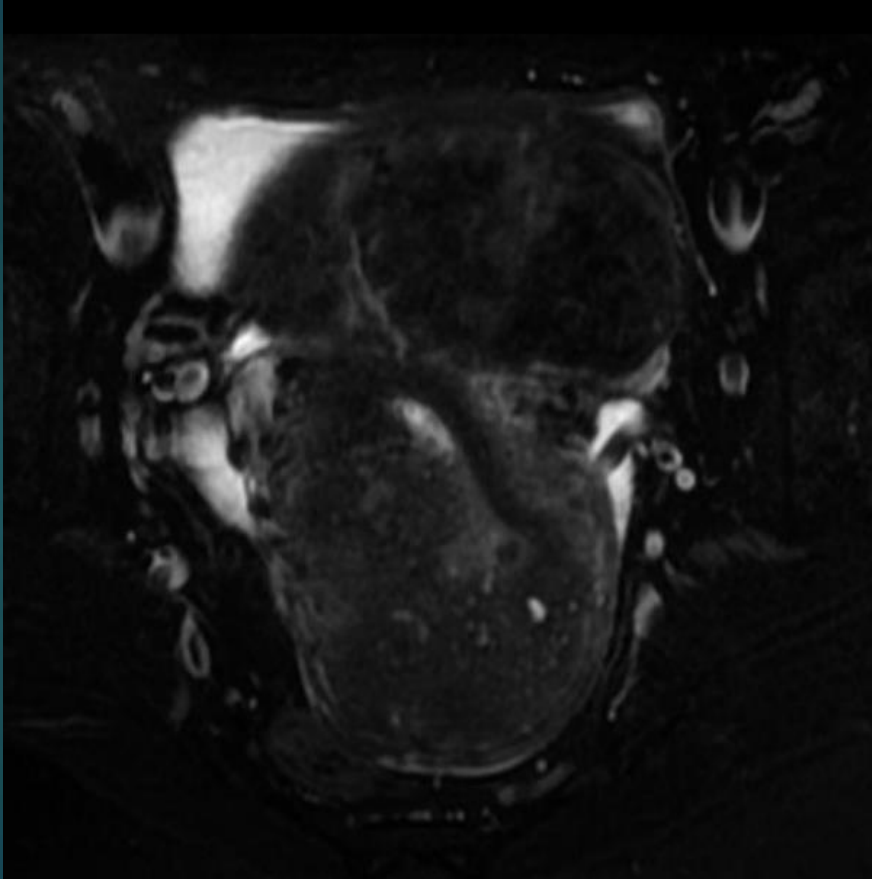
FOKAL ADENOMYOZIS



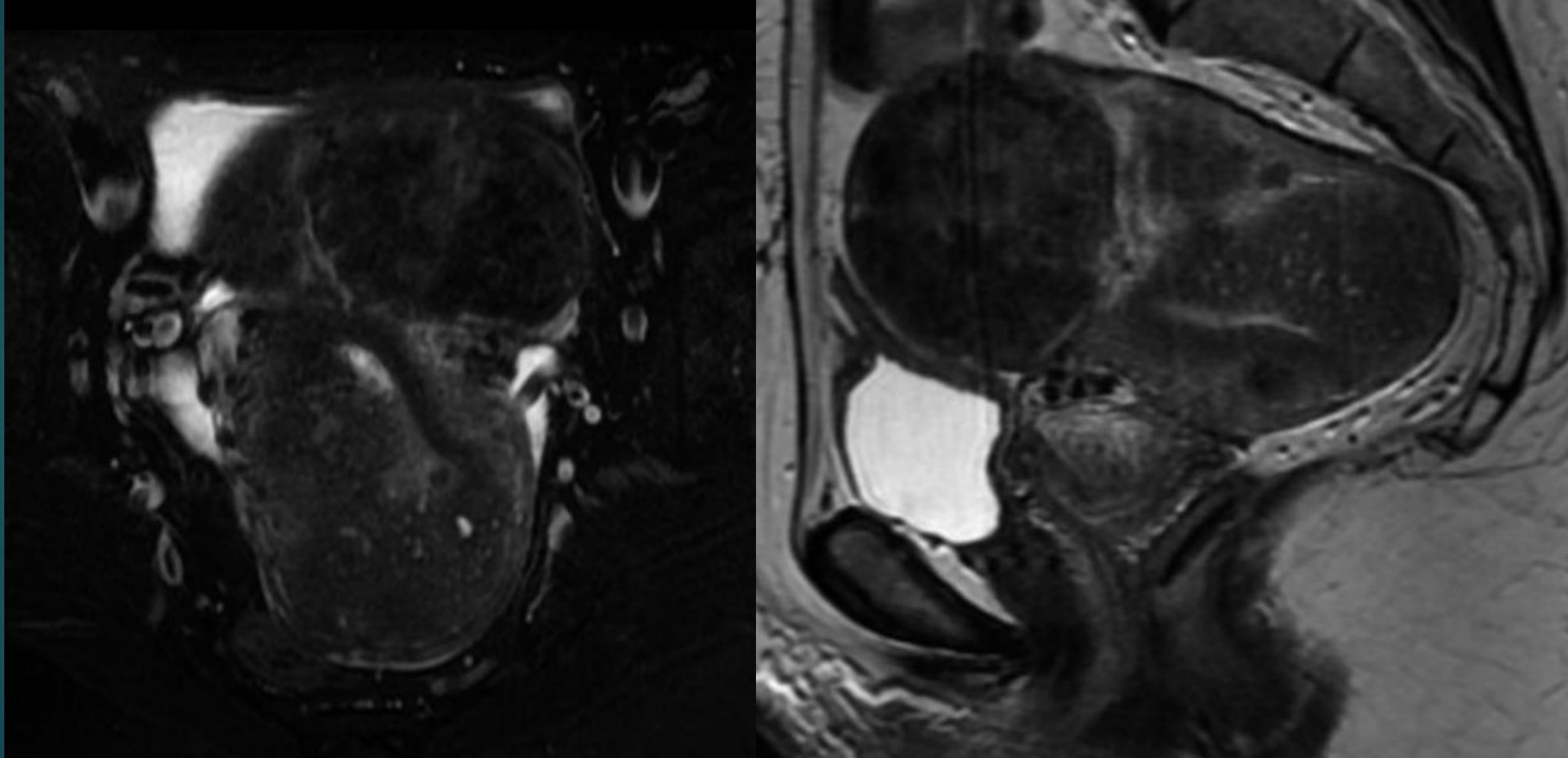


KİSTİK ADENOMYOMA



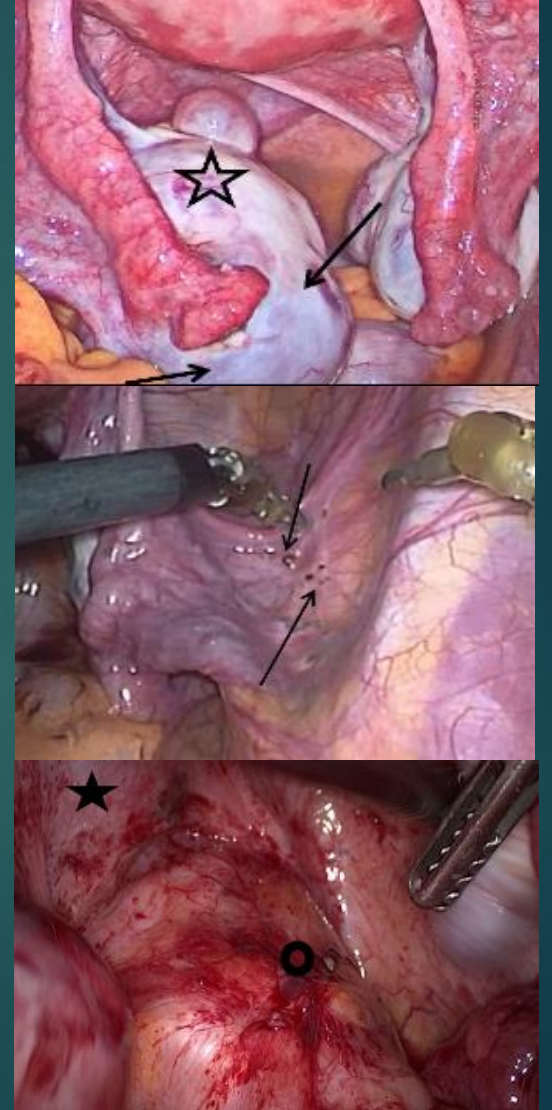


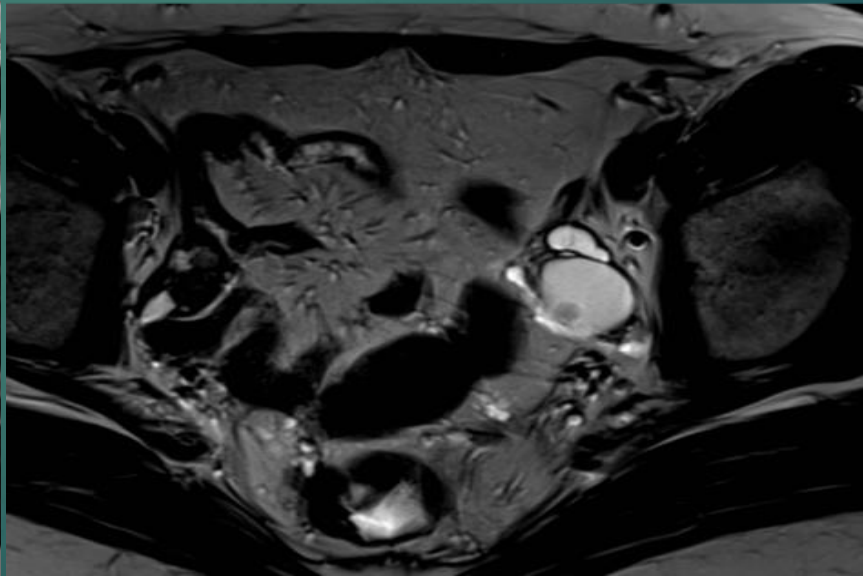
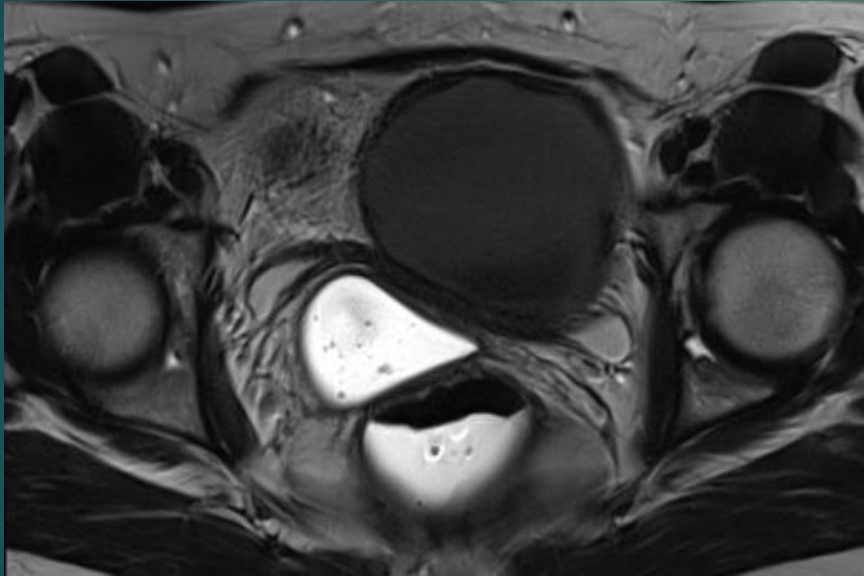
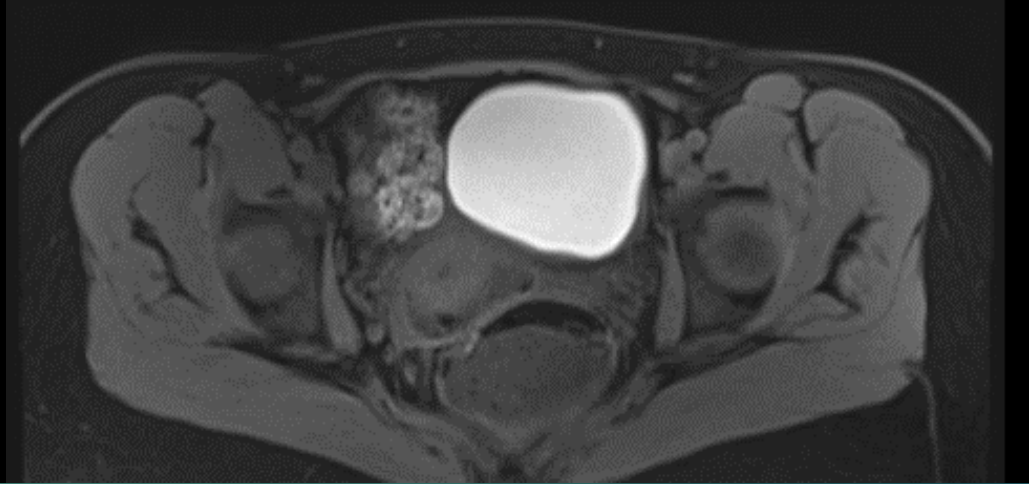
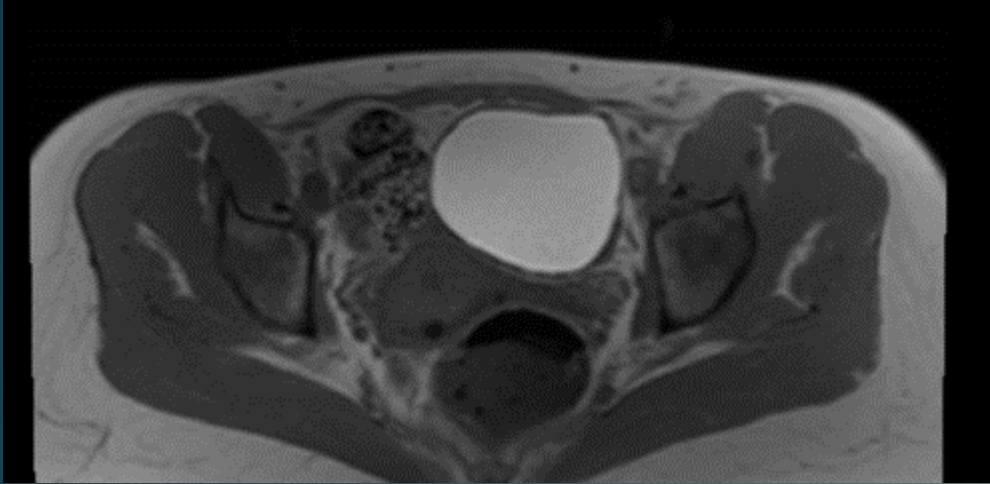
MYOM VE ADENOMYOZİS

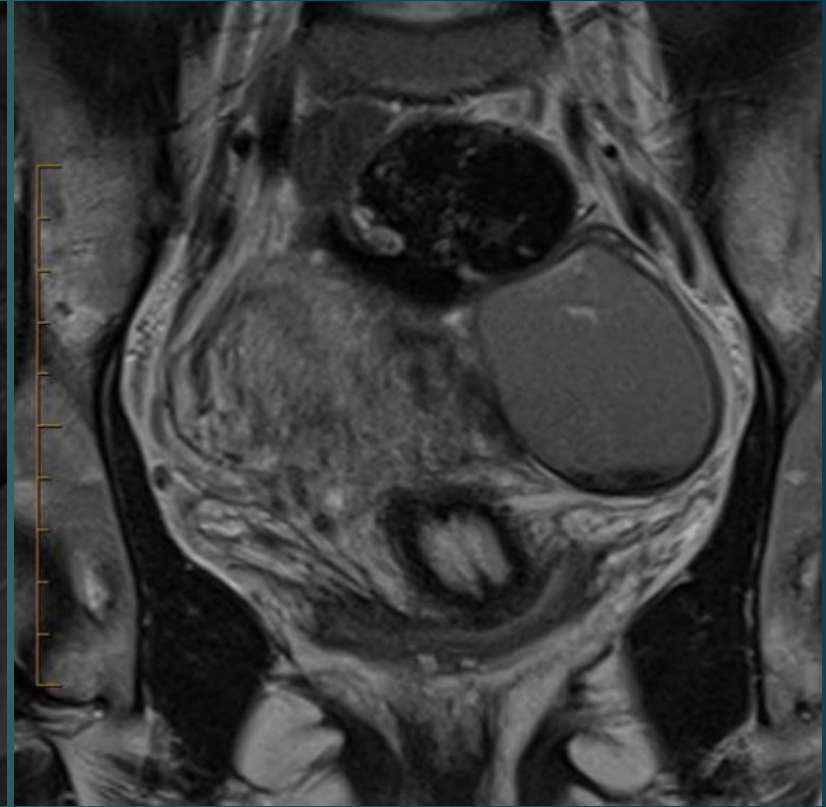
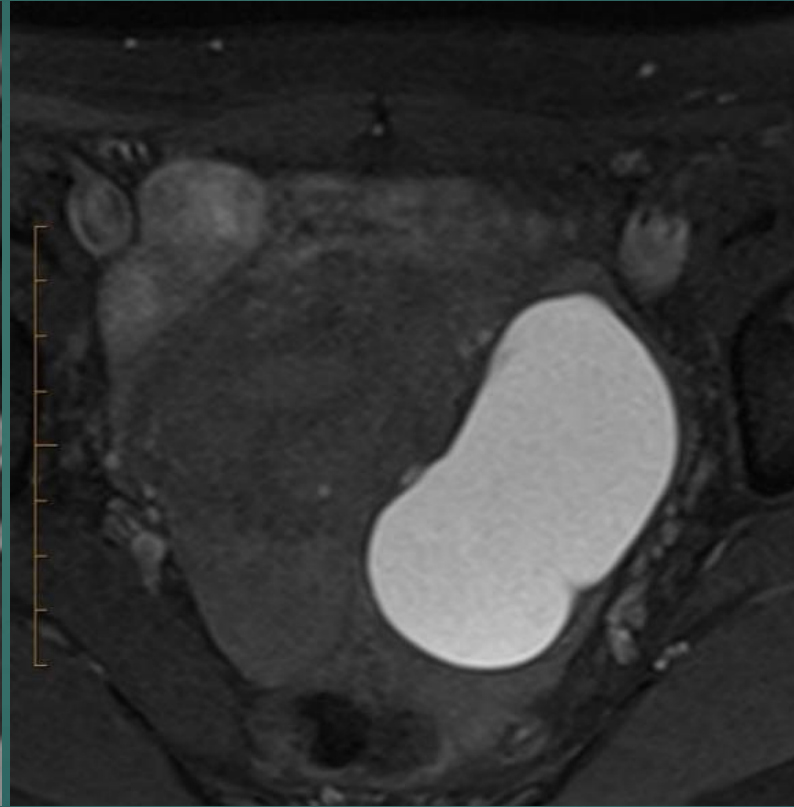
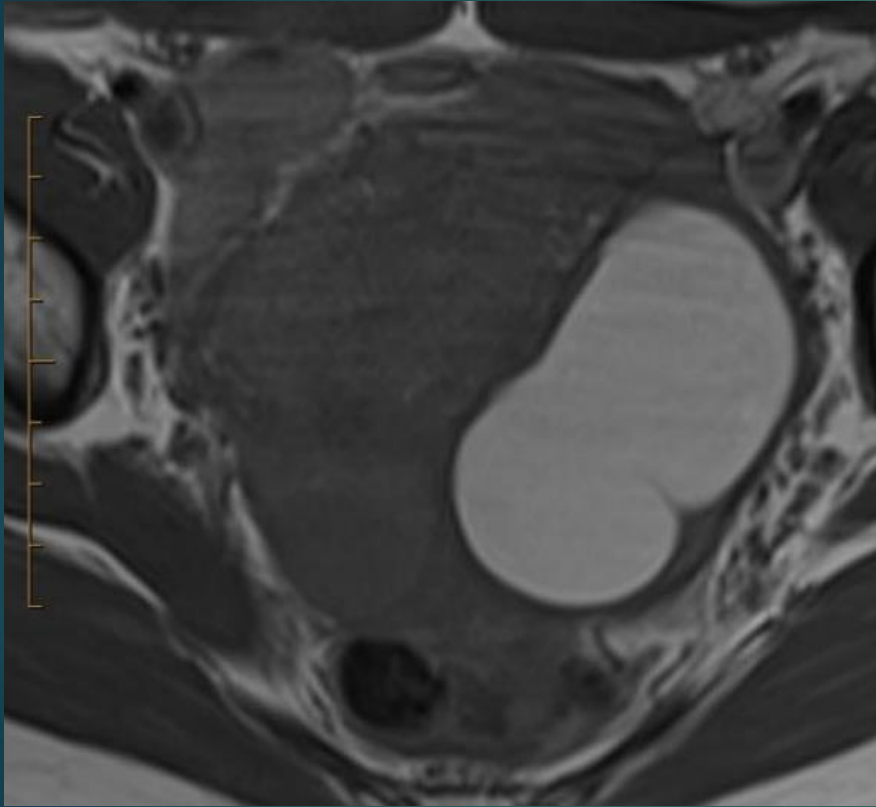


ENDOMETRİOZİS

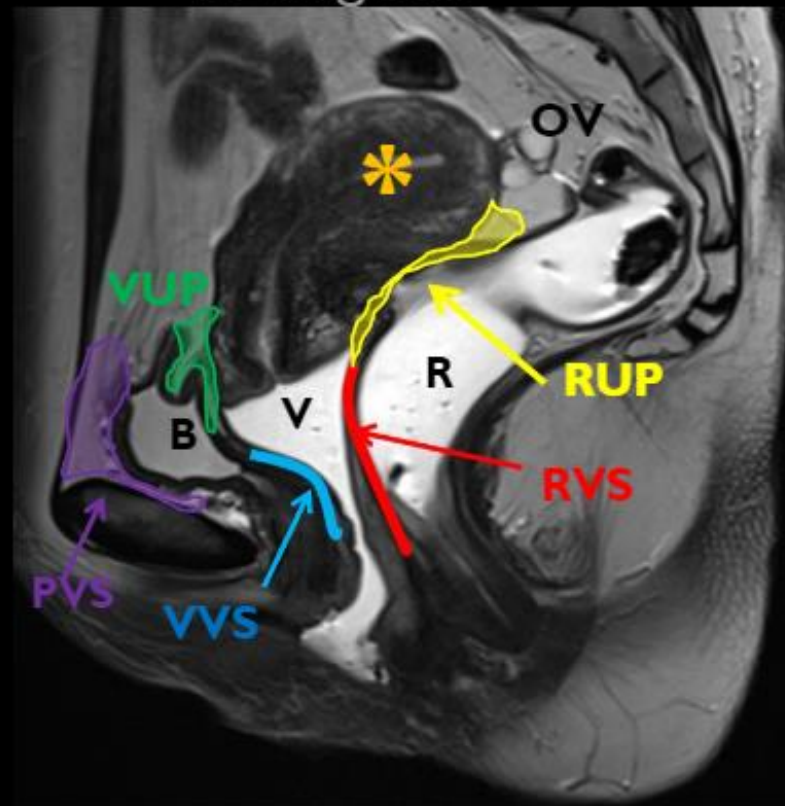
- ▶ Endometrial dokunun uterus dışında yerleşimi.
- ▶ Üreme çağındaki kadınların yaklaşık %10'u.
- ▶ Yüzeyel peritoneal,derin pelvik ve ovaryan yerleşim.
- ▶ 5 mm'nin altında hemorajik olmayan implantlar!!!!!!!!!!
- ▶ Preop haritamada en güvenilir modalite.







T2 Sagittal



Anterior compartment:

- Prevesical space (PVS)
- Bladder (B)
- Vesicouterine pouch (VUP)
- Vesicovaginal septum (VVS)

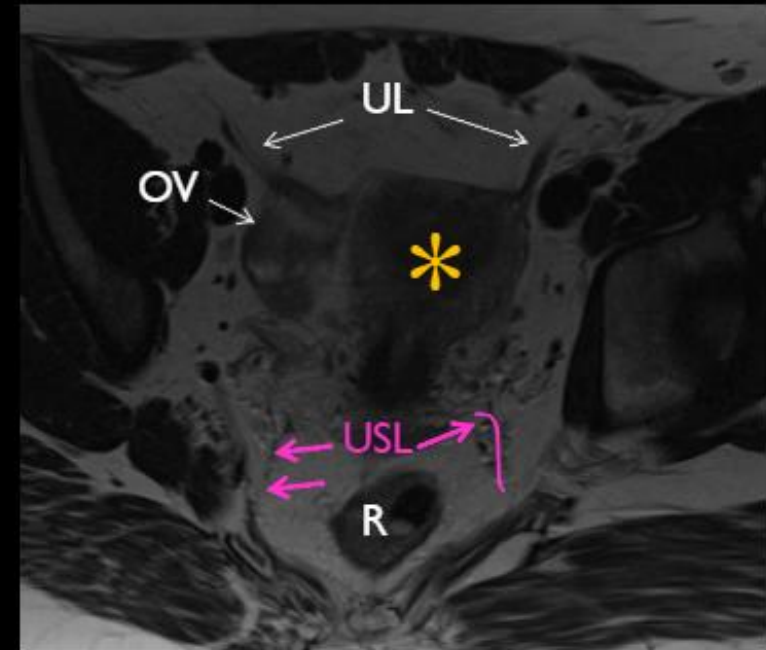
Middle compartment:

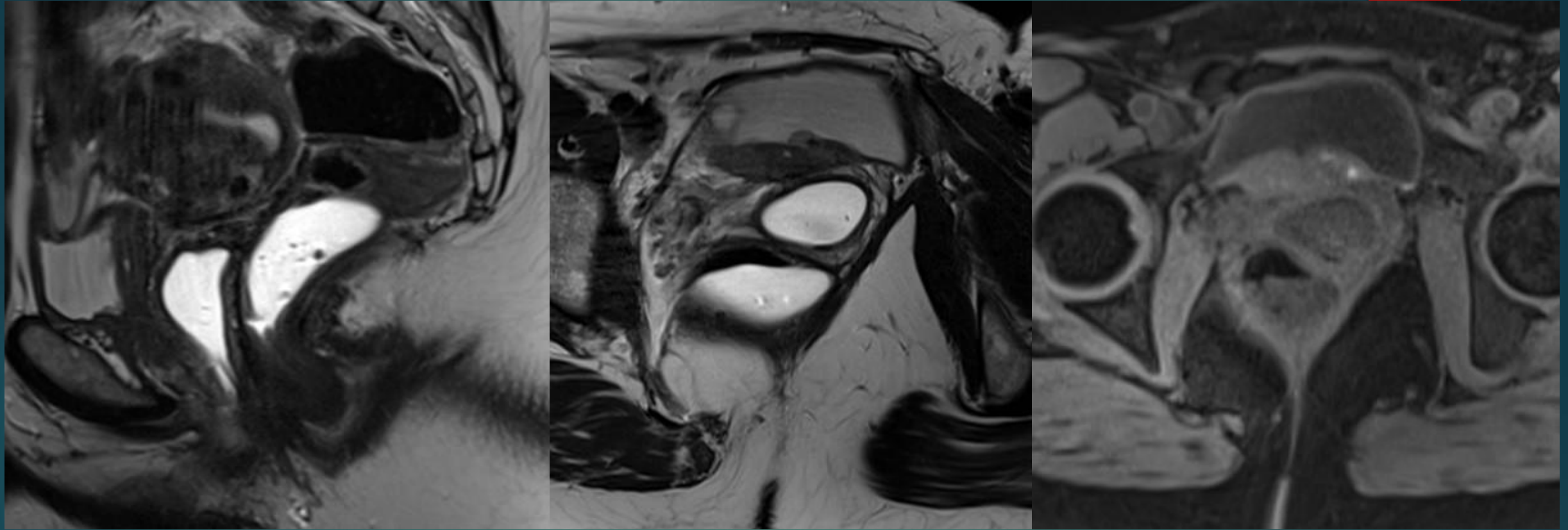
- Uterus (*)
- Vagina (V)
- Ovary (OV)
- Fallopian tube
- Uterine ligaments (UL)

Posterior compartment

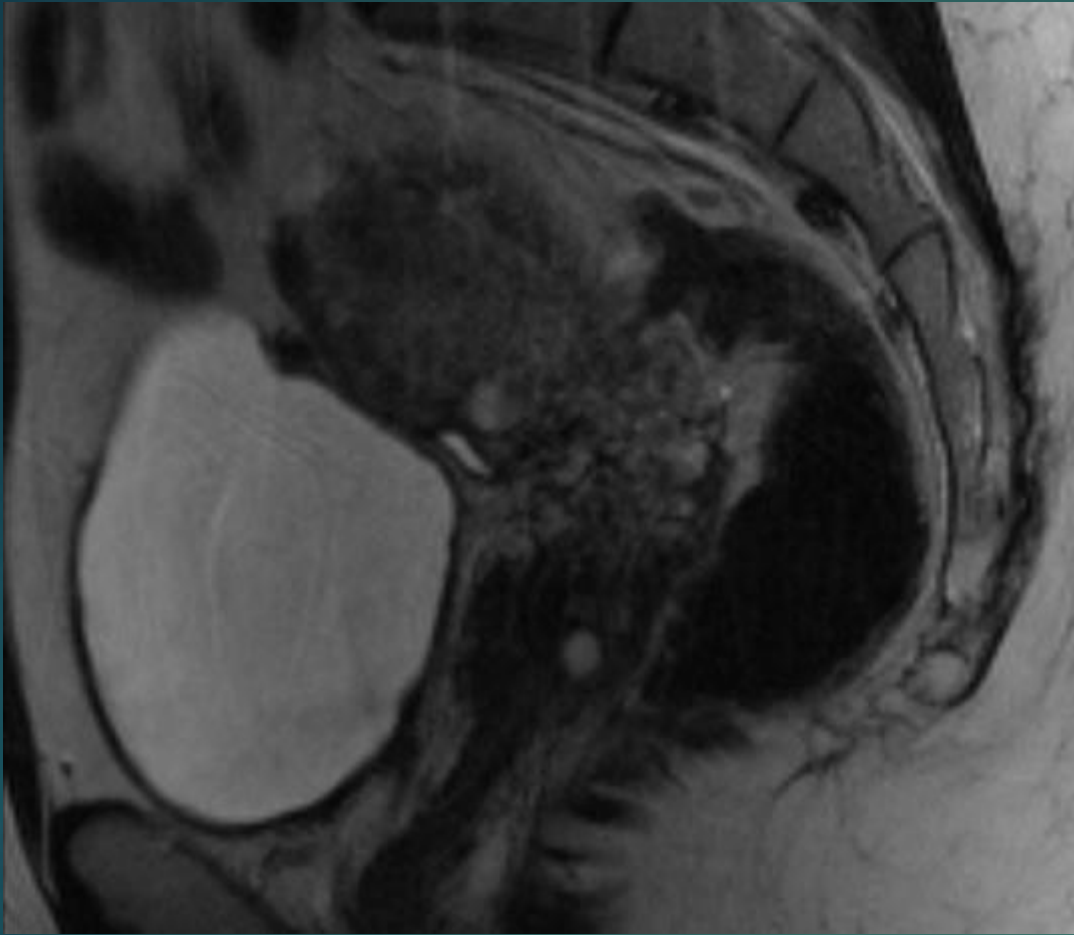
- Rectum (R)
- Rectovaginal septum (RVS)
- Rectouterine pouch (RUP)
- Uterosacral ligament (USL)

T2 Axial

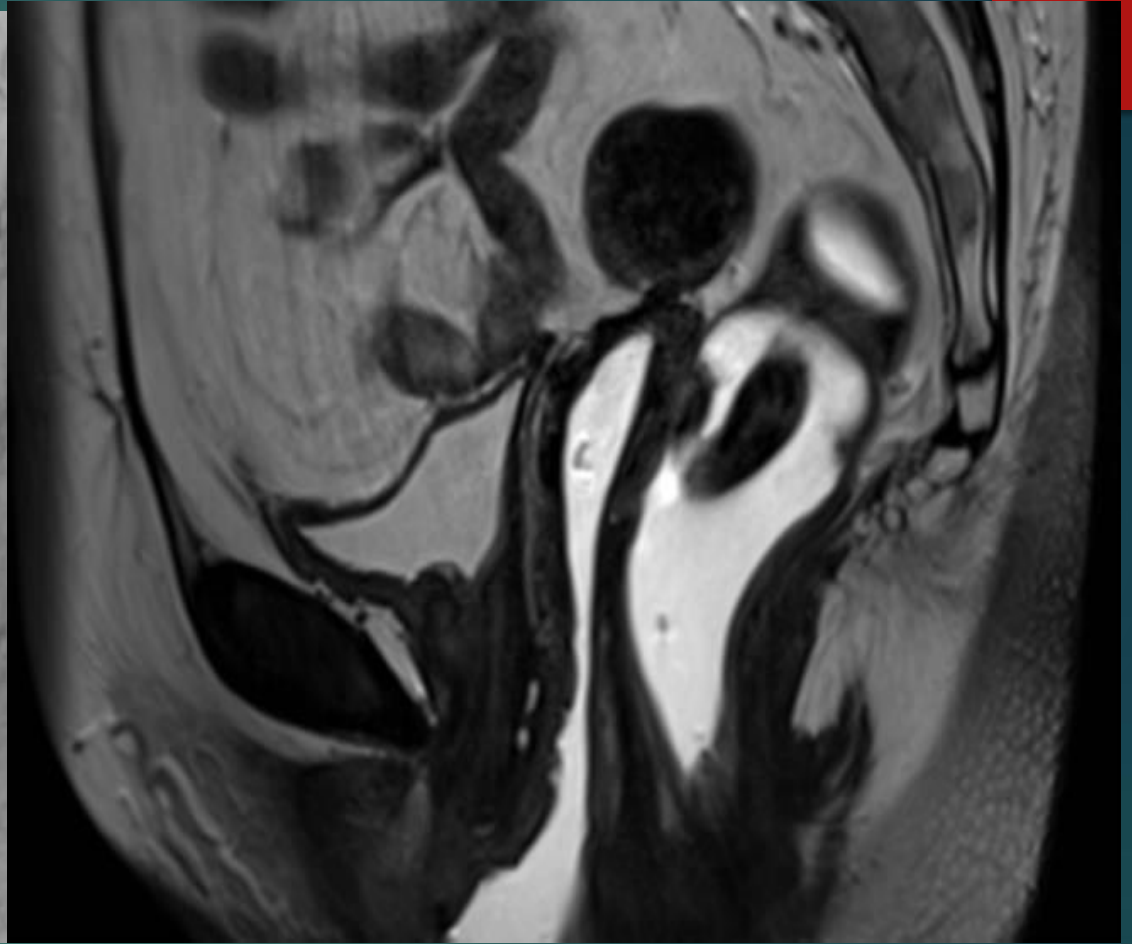




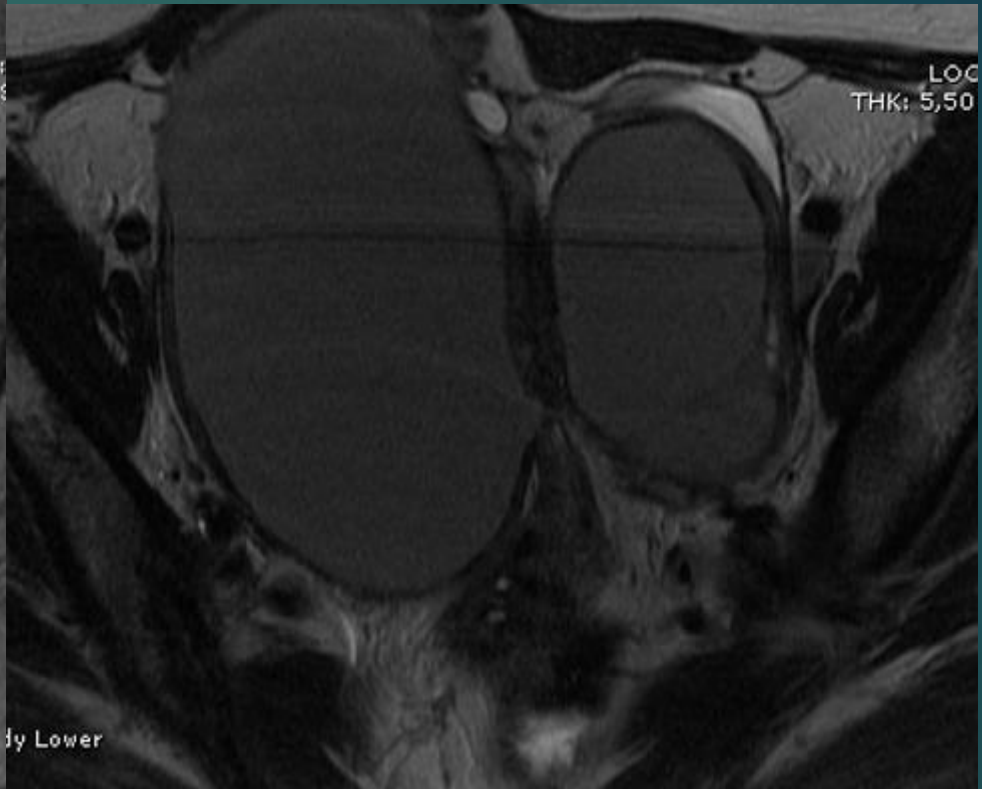
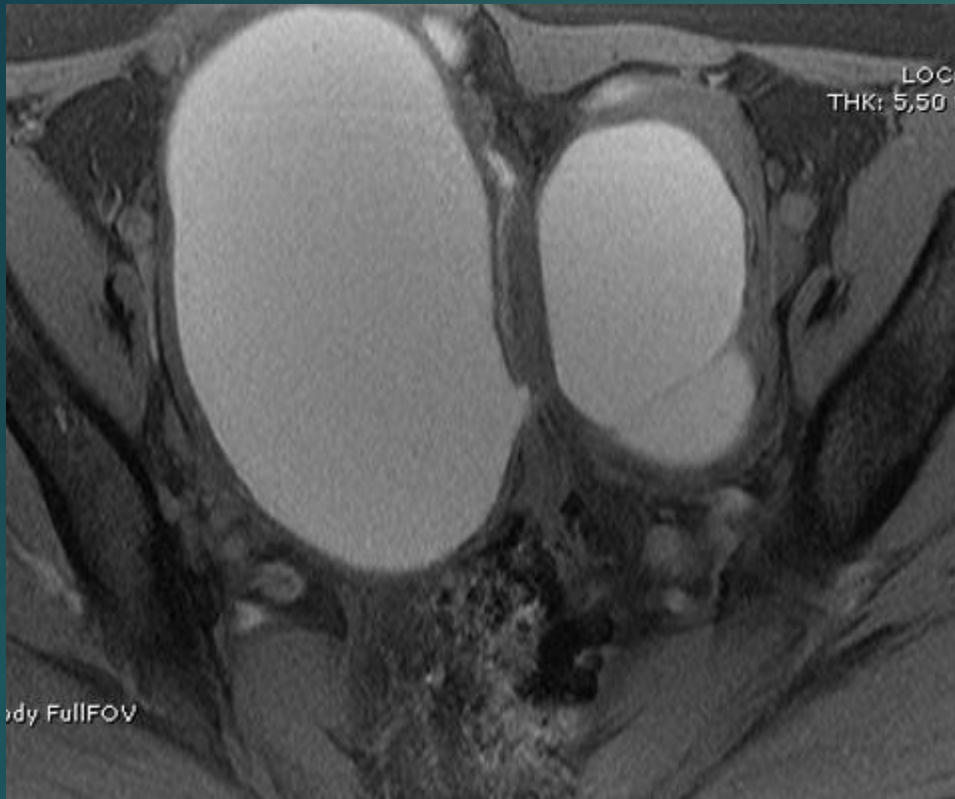VVS tutulumu



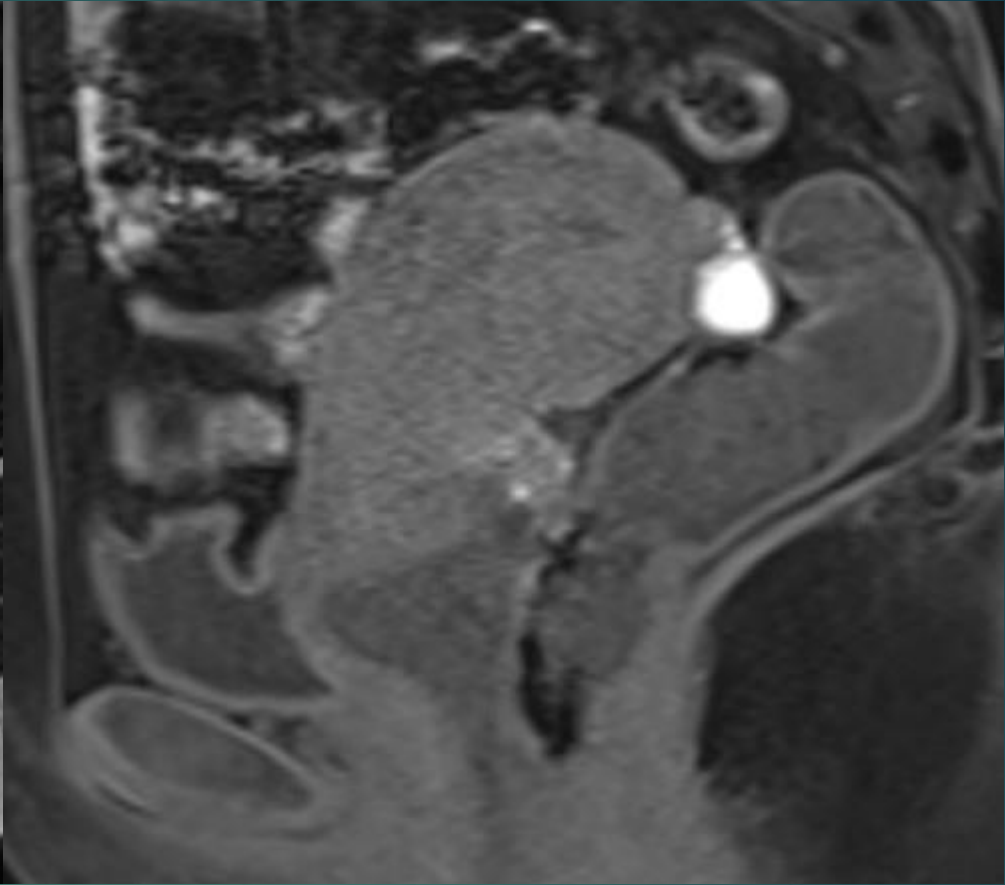
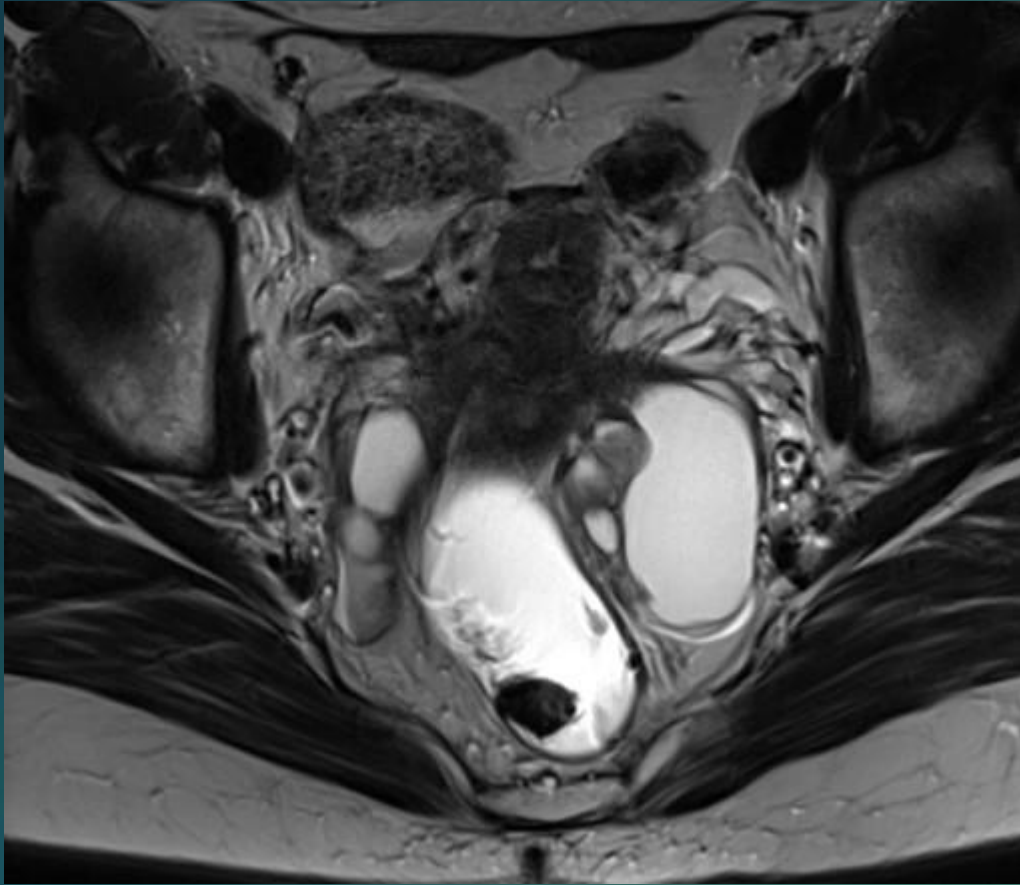
VUP tutulumu



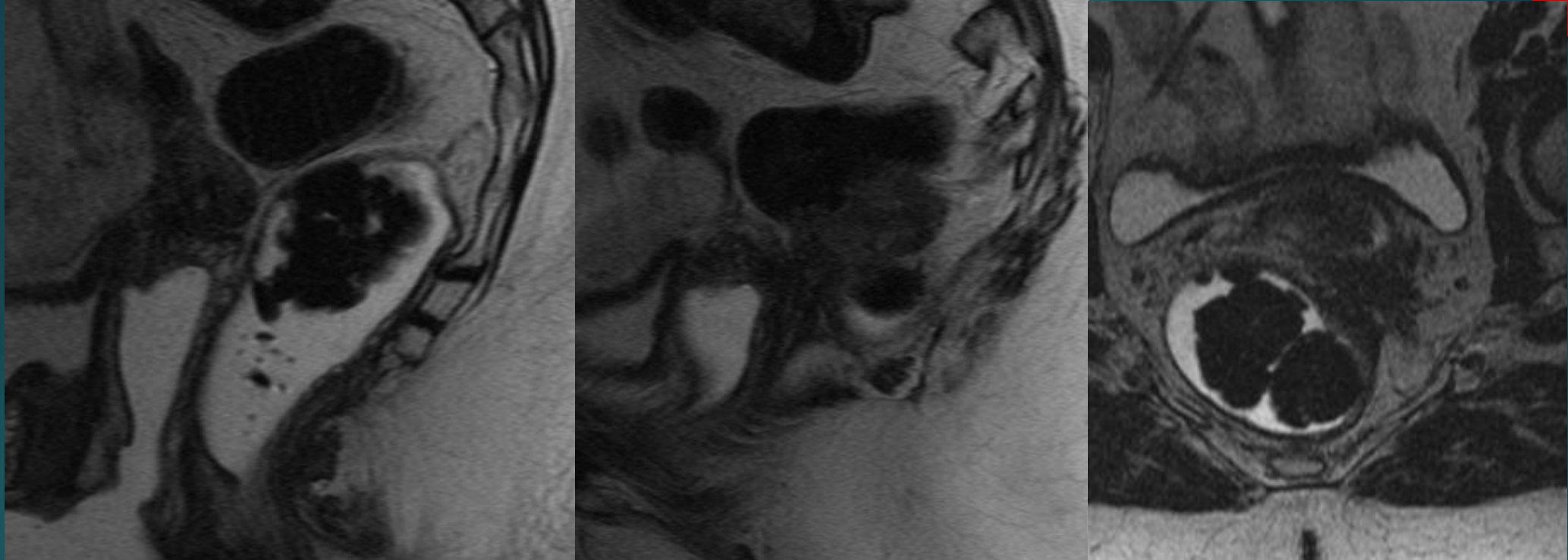
VVS tutulumu



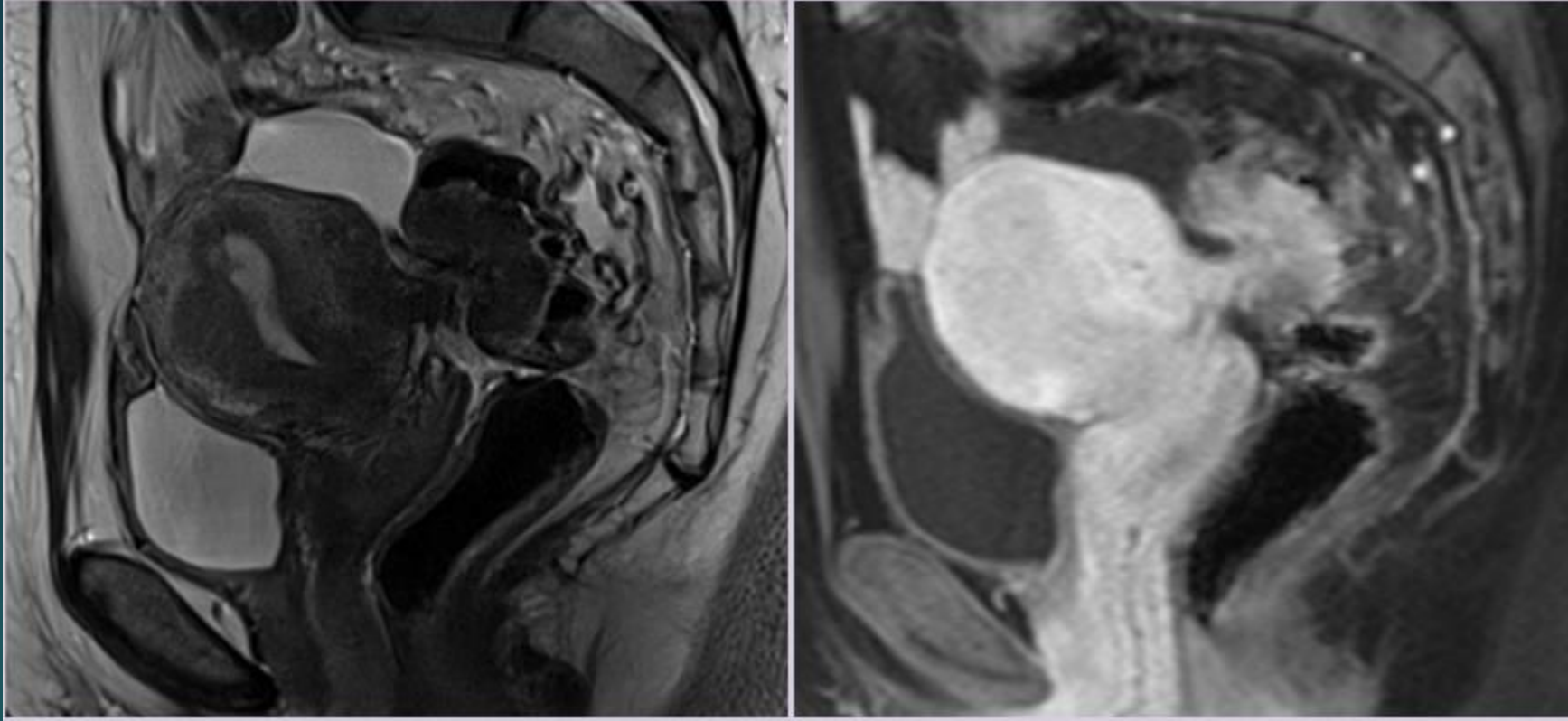
KISSING OVER
Shading sign



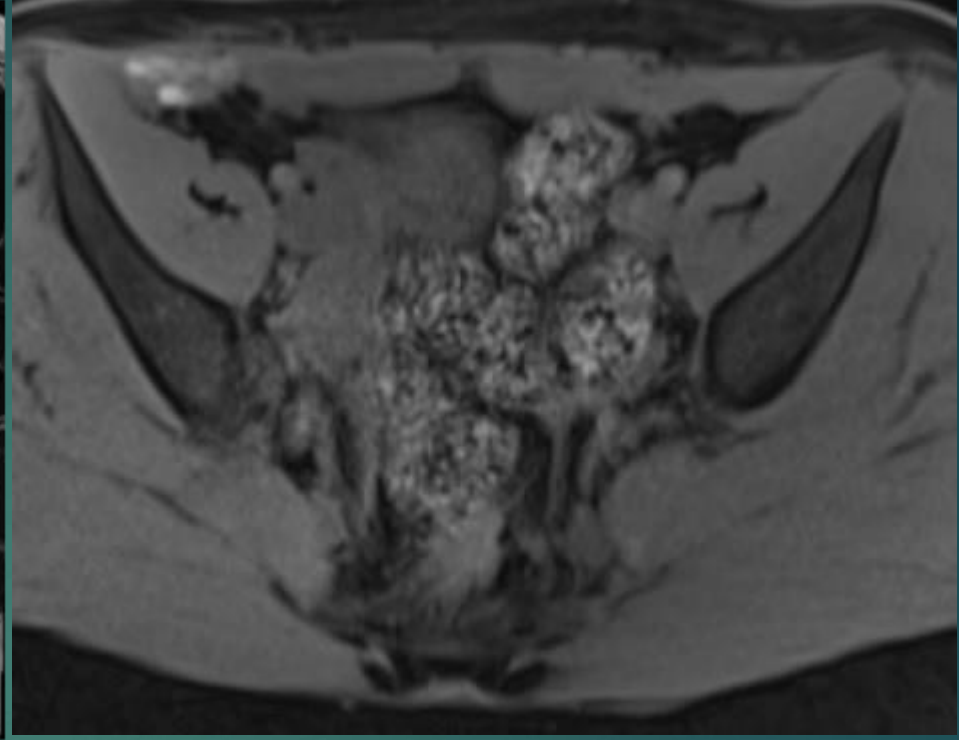
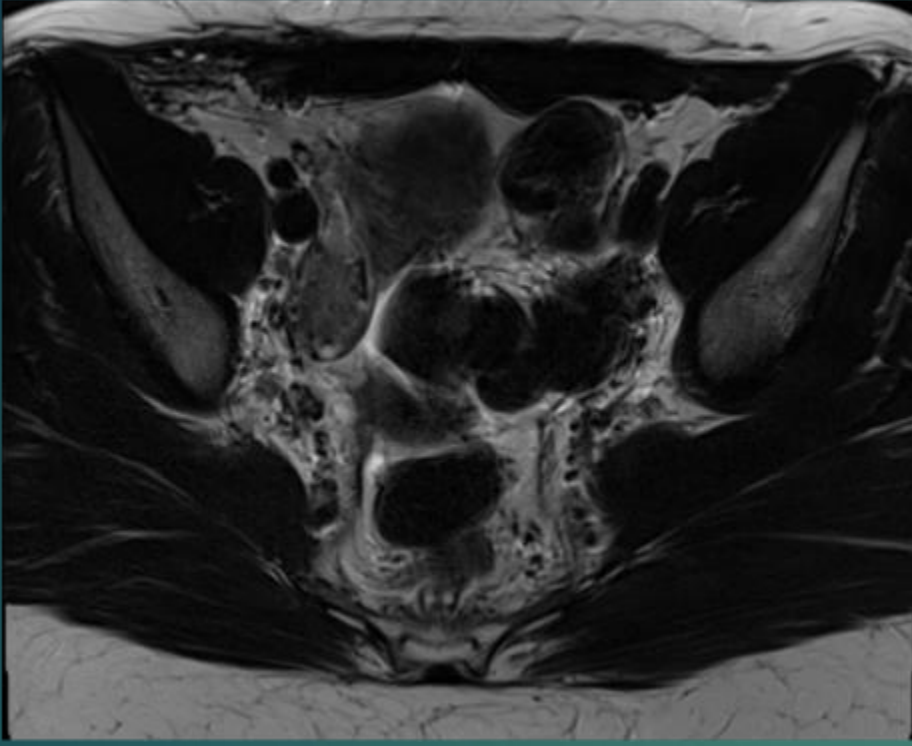
KISSING OVER
RUP ve RVS tutulumu



RVS tutulumu

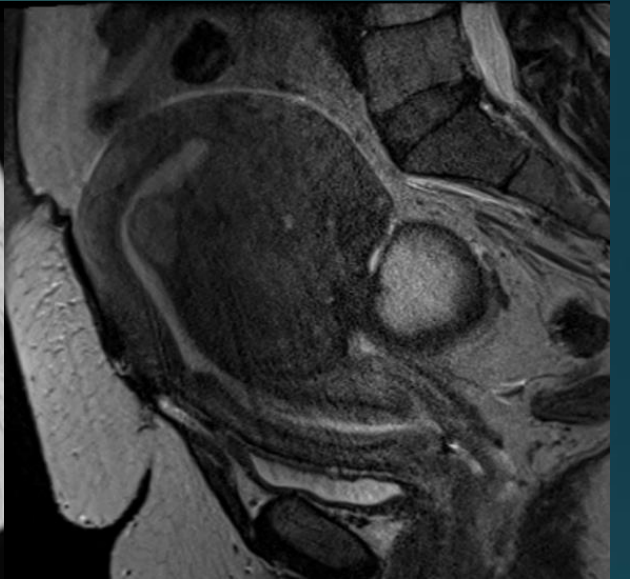
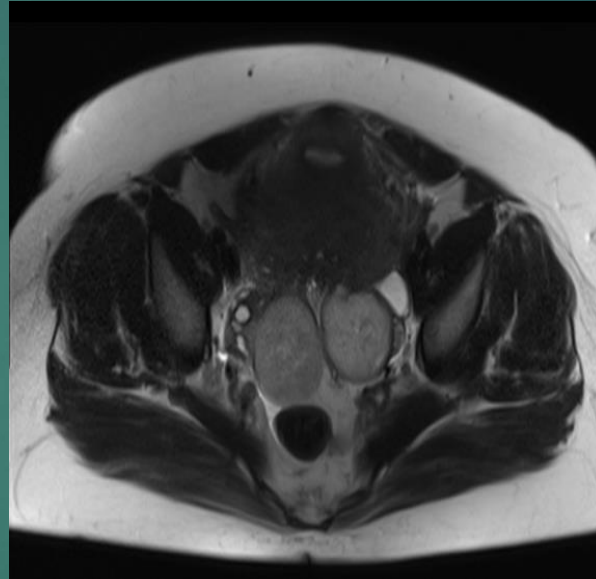
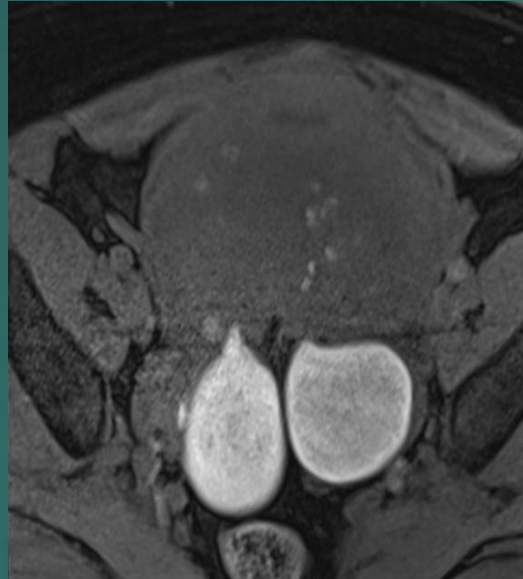
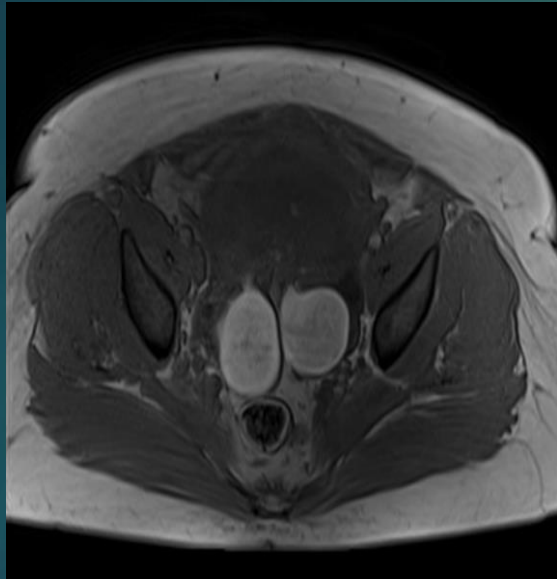


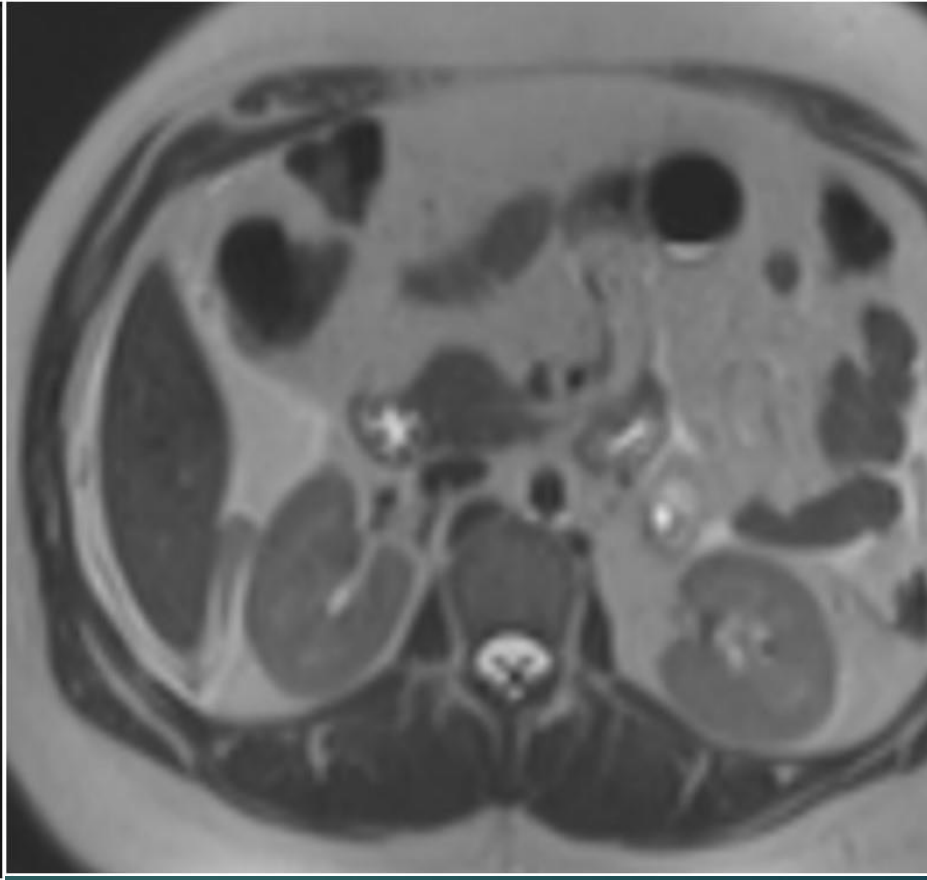
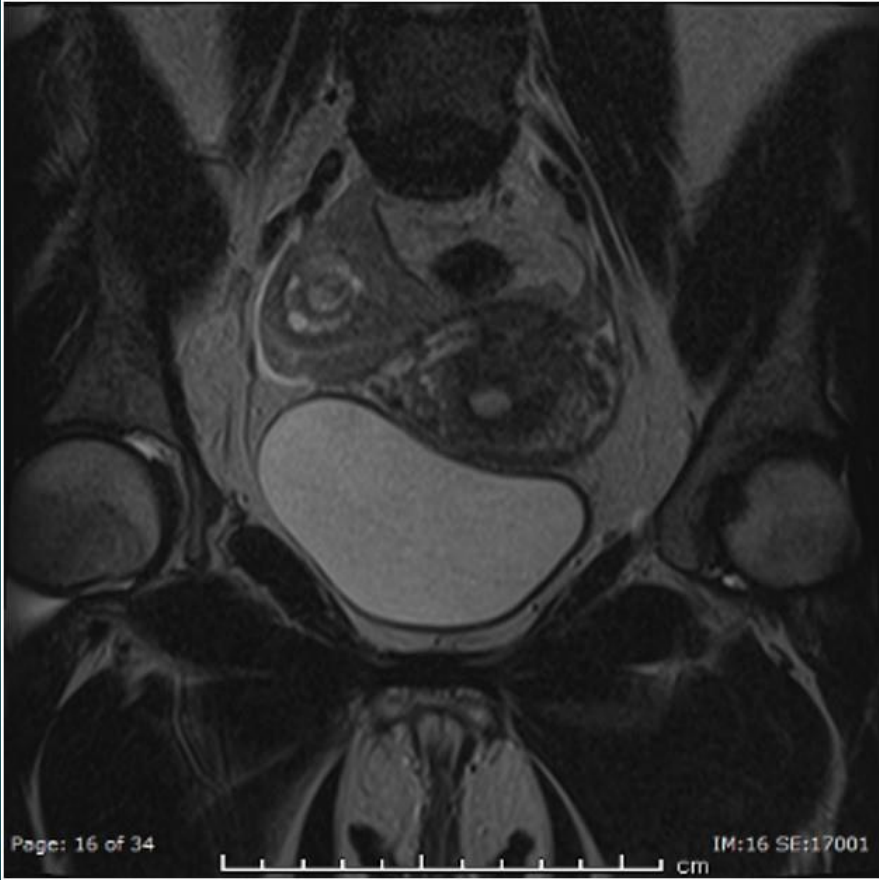
REKTUM ÖN DUVAR tutulumu
Mushroom sign



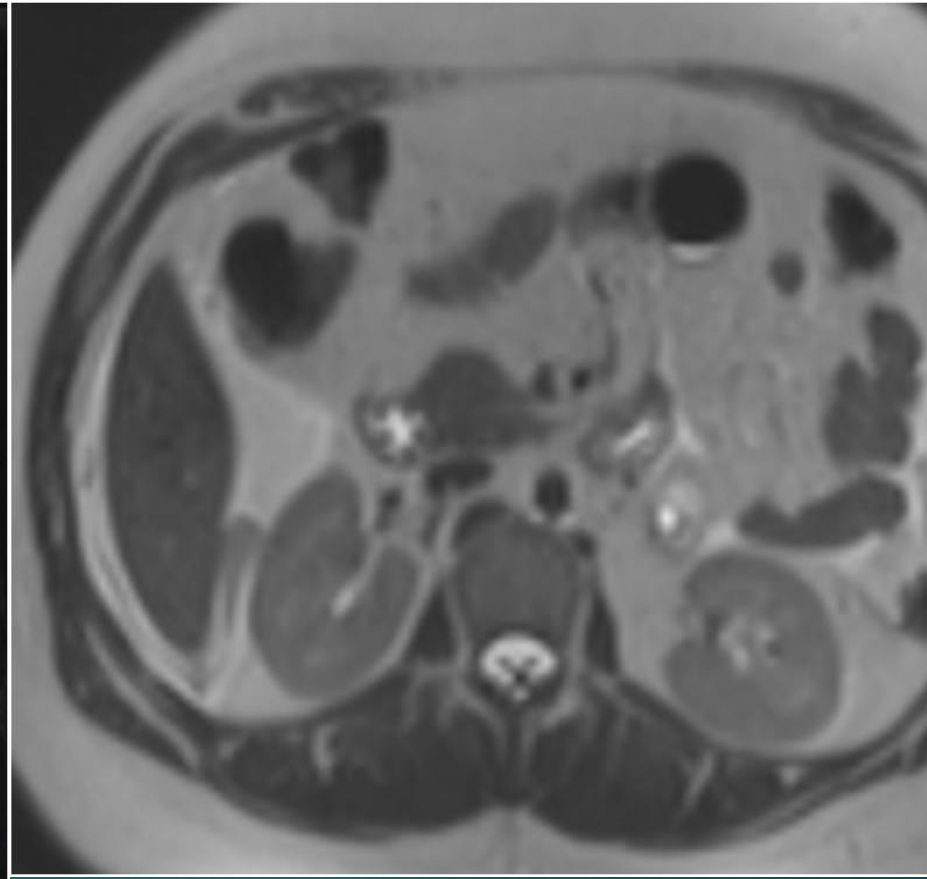
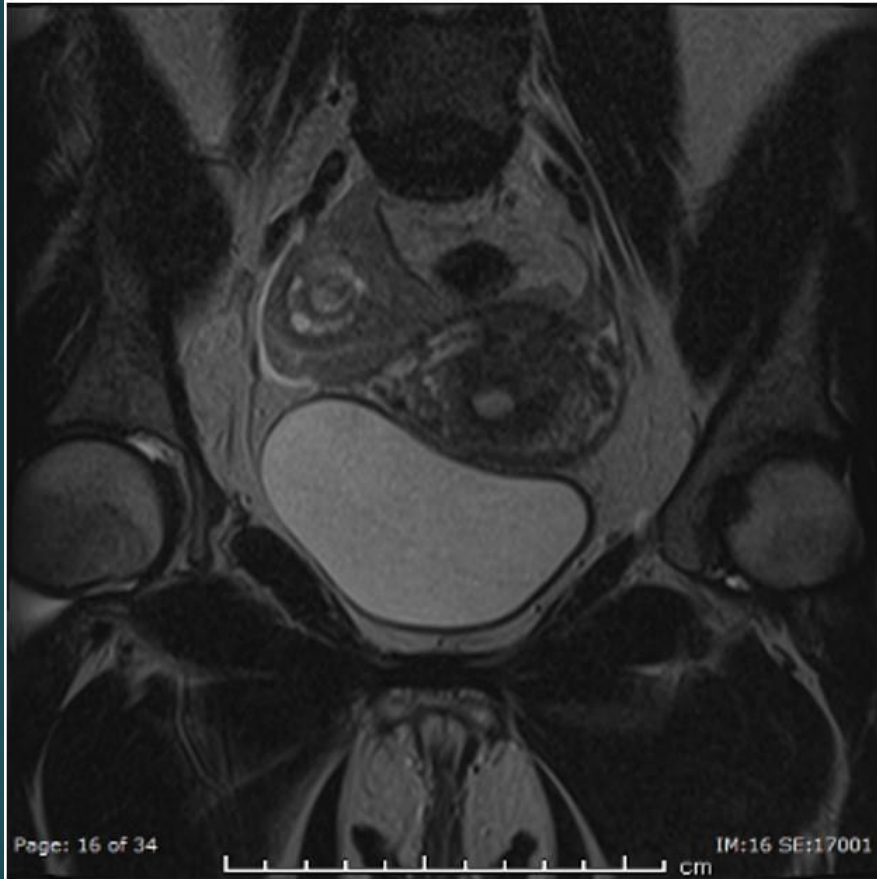
BATIN ÖN DUVAR tutulumu

ENDOMETRIOMA+ADENOMYOSIS

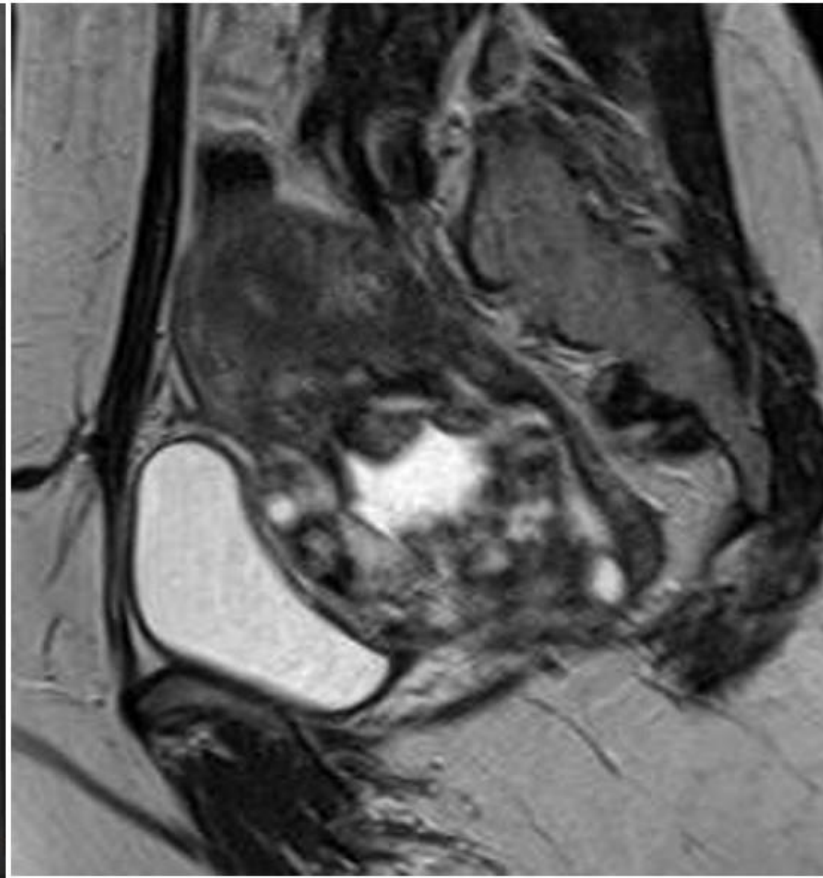
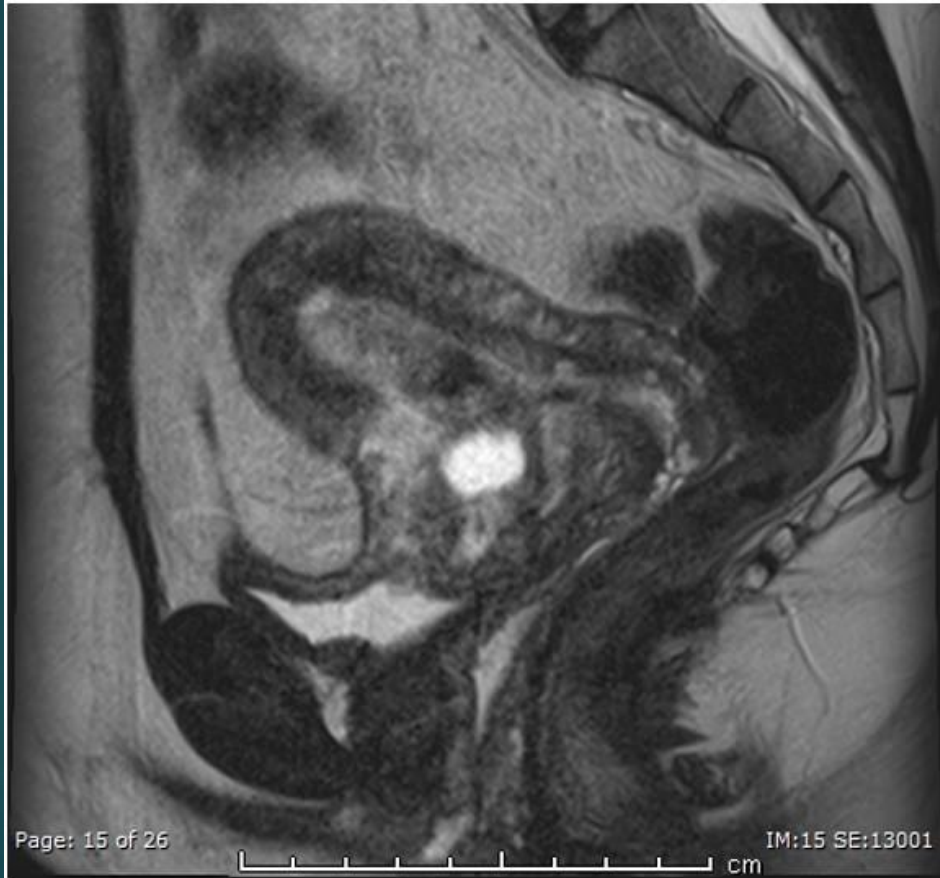



AMPULLER EKTOPİK GEBELİK



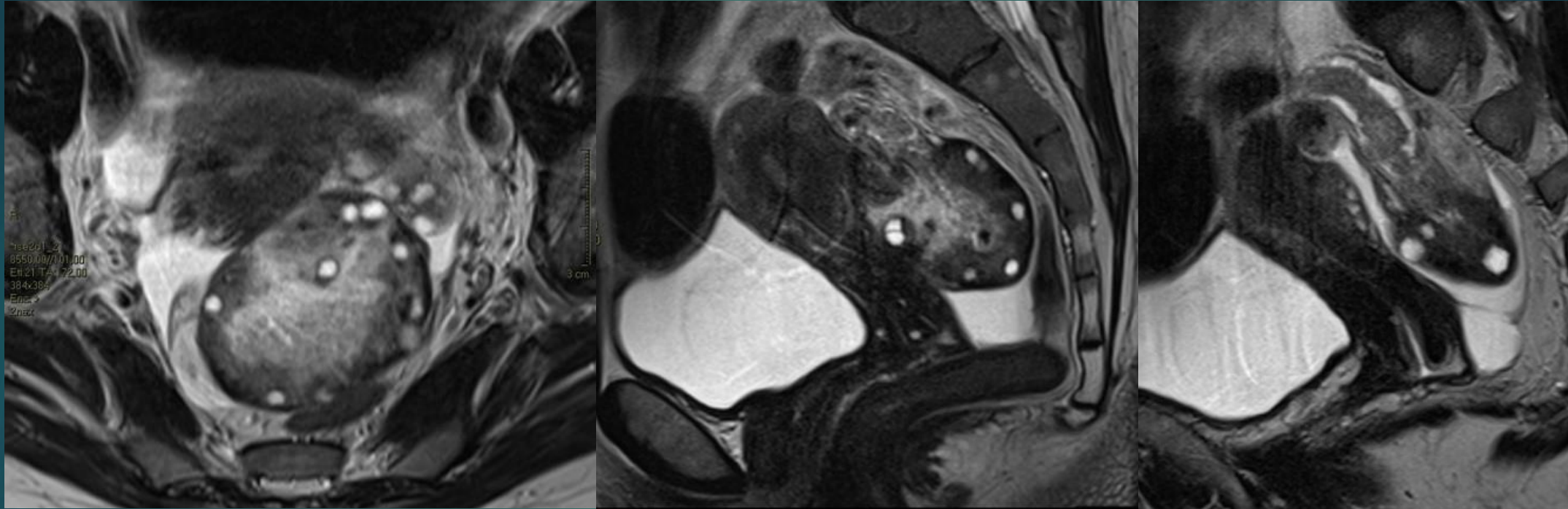
SKAR YERLEŞİM



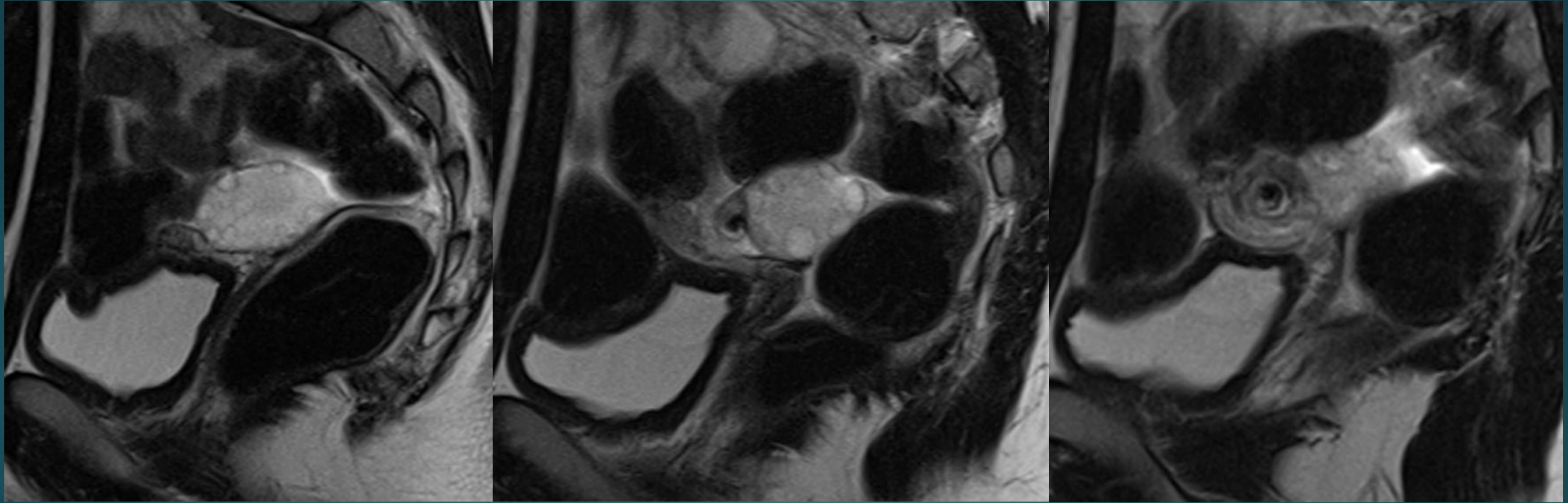
ADNEKSİYAL TORSİYON

- ▶ Over ve/veya fallop t p n n kendi etrafında en az bir tur d nmesi
- ▶ Adneksiyal kitle,prepubertal kız  ocukları,hamilelik
- ▶ Acil tanı ve tedavi overlerin kurtarılması a ısından  OK  NEMLİ...
- ▶ RDUS:Akım varlıđı torsiyonu EKARTE ETTİRMEZ...
- ▶ GİRDAP BULGUSU spesifik.

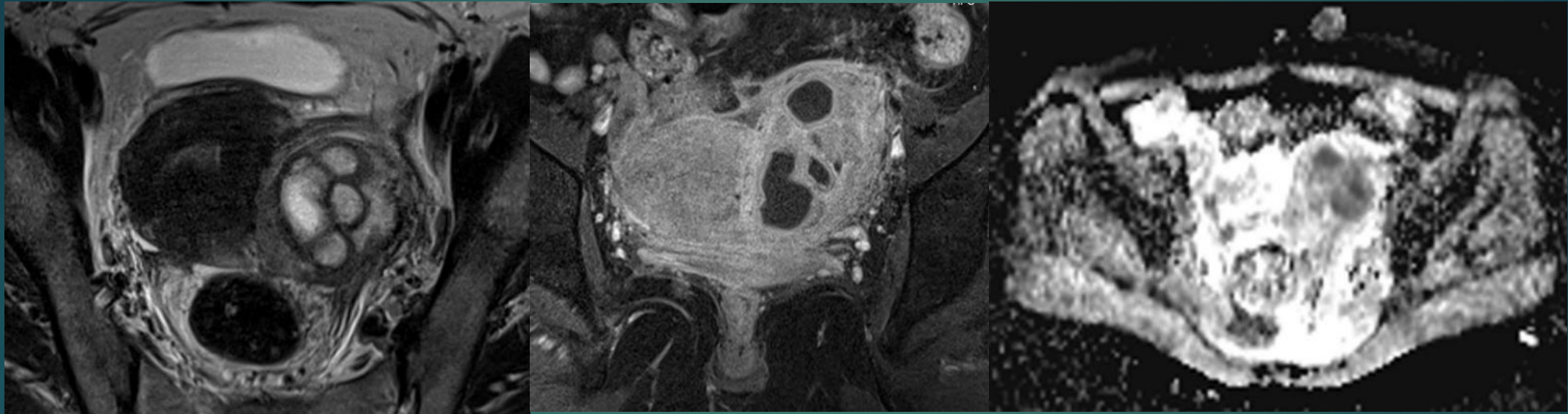
TORSİYON



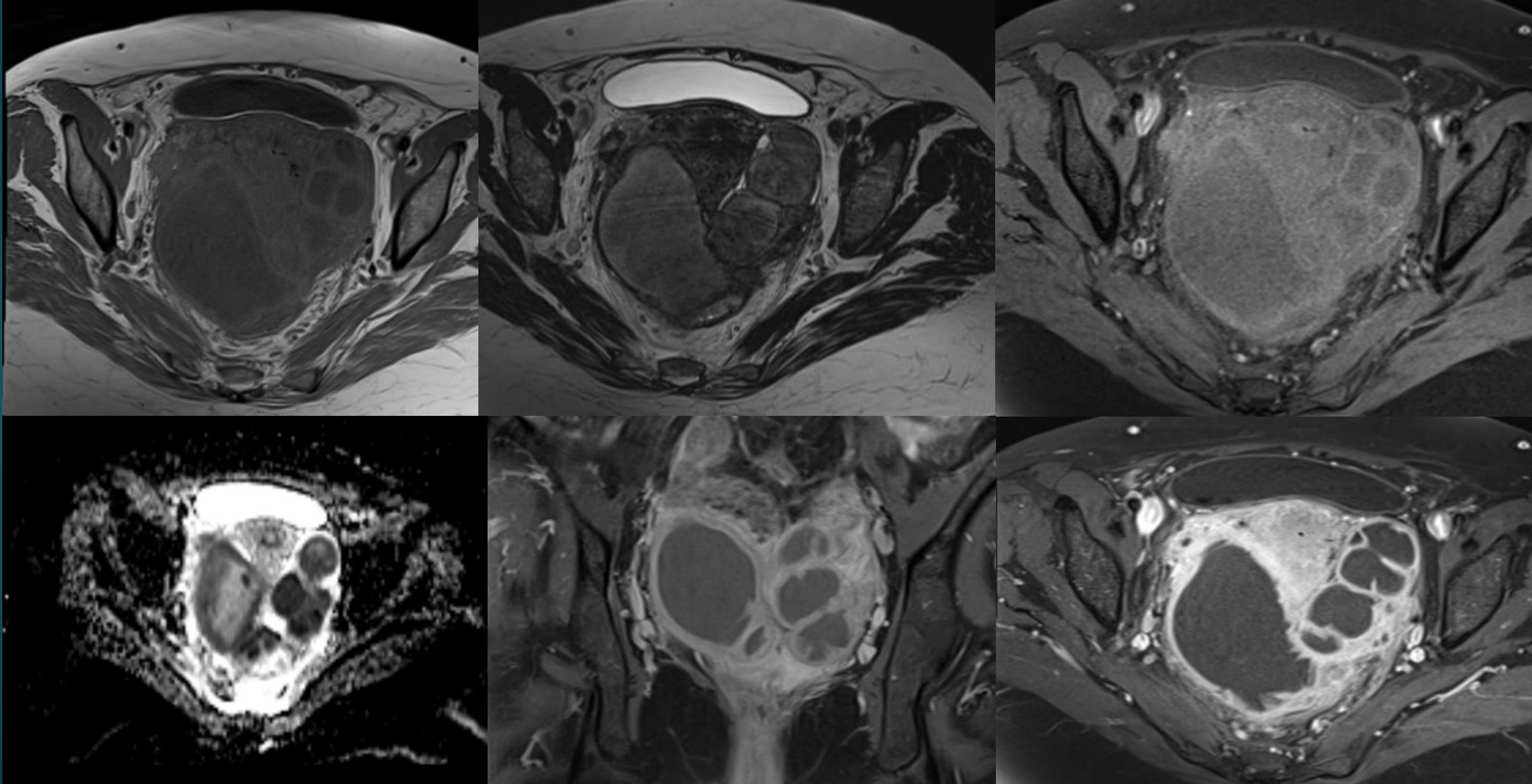
TORSİYON



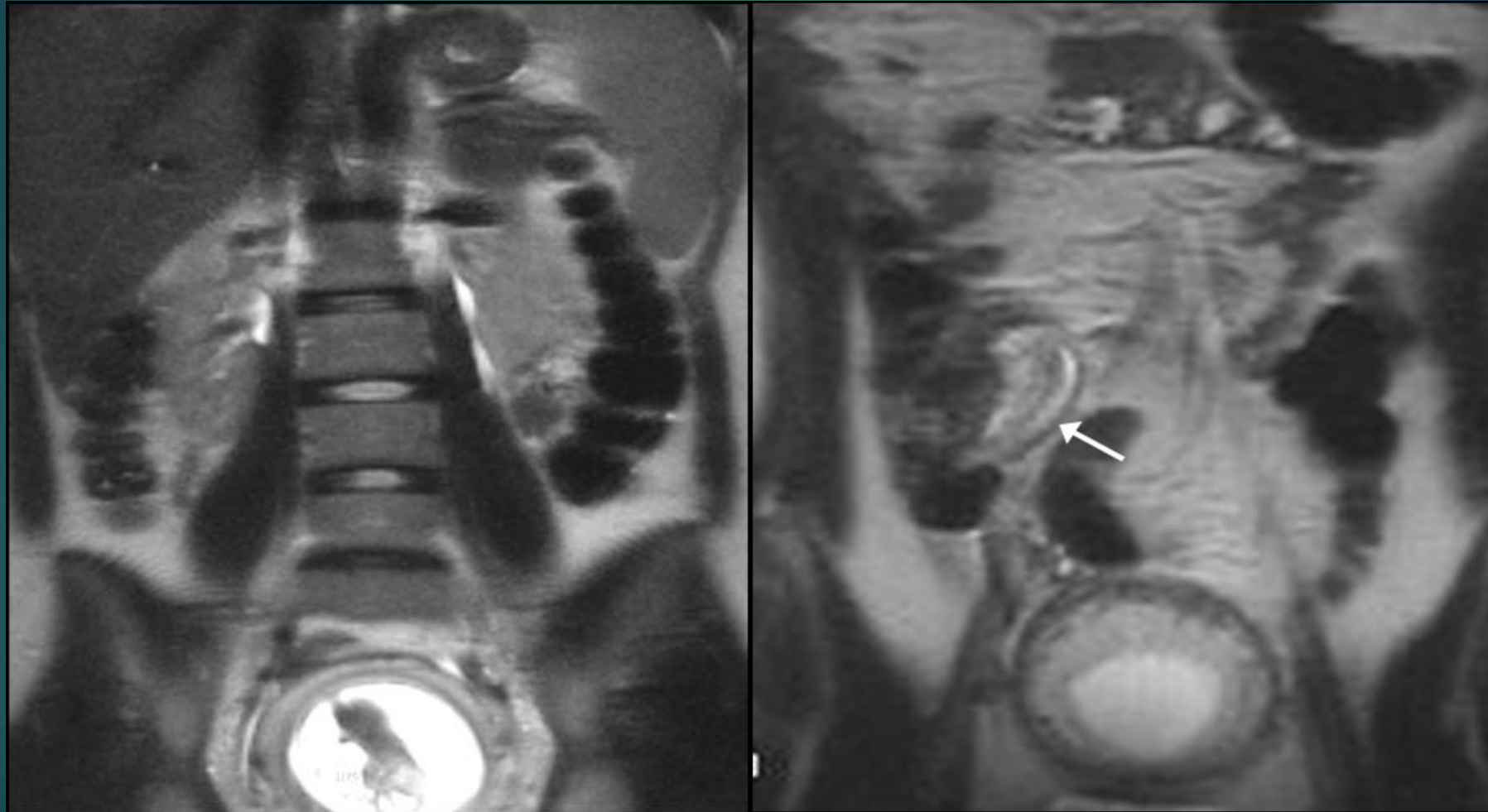
TUBAOVARYAN ABSE



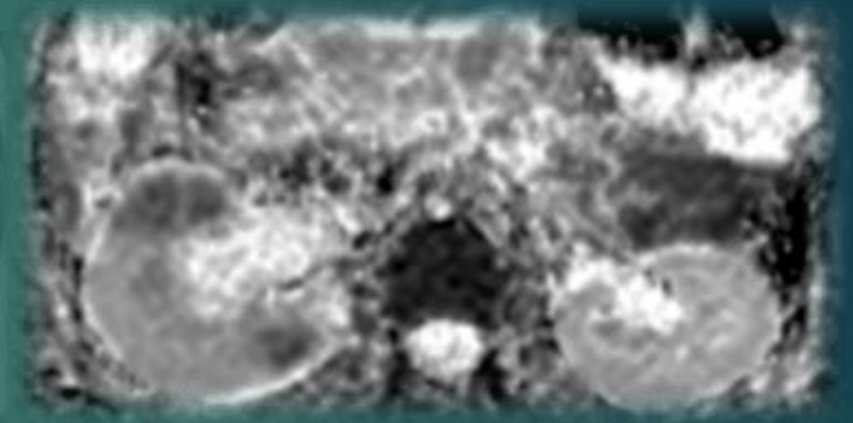
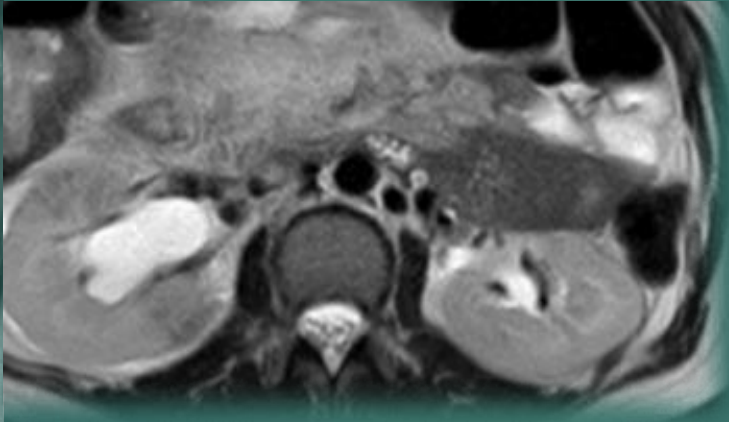
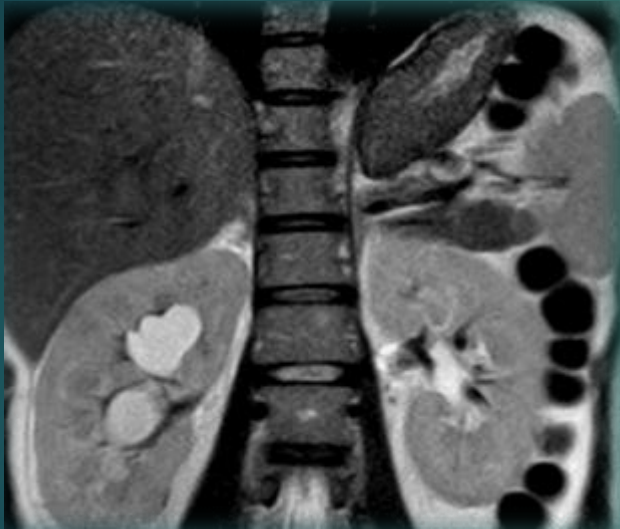TUBAOVARYAN ABSE



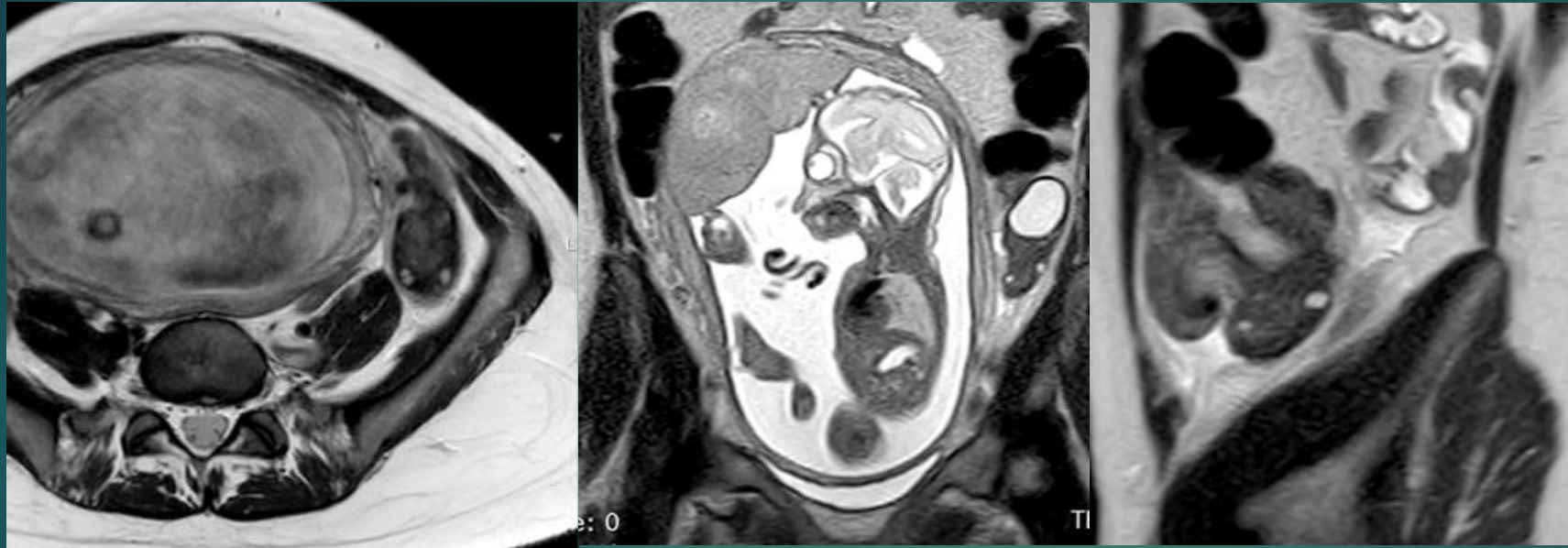AKUT APANDISIT



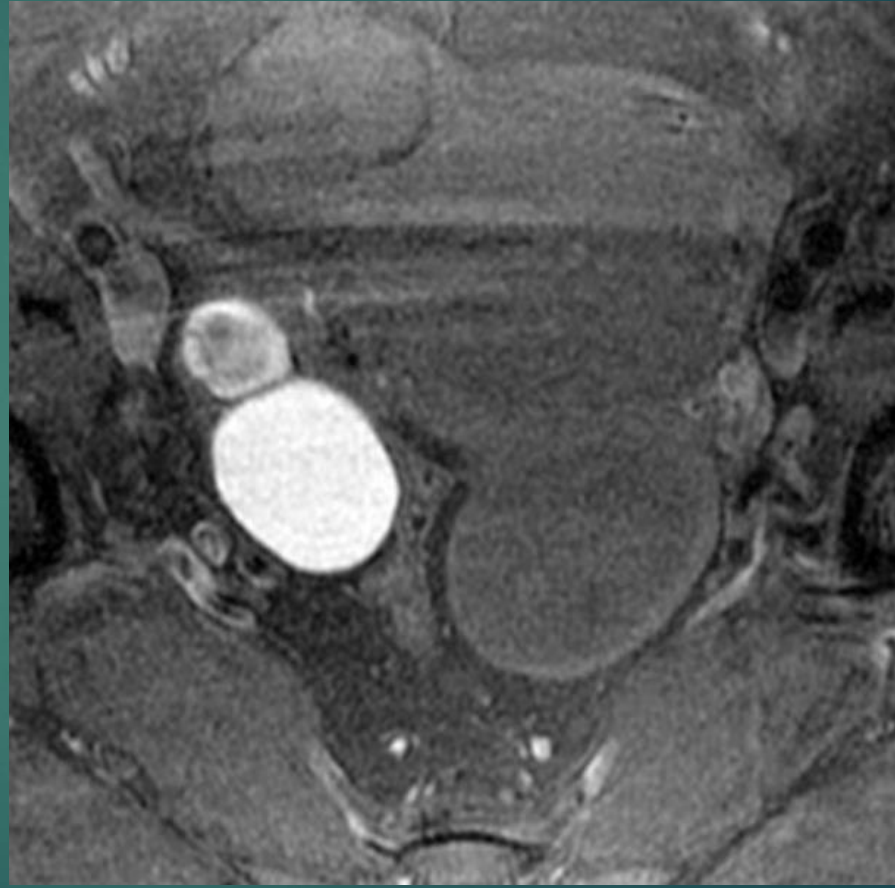
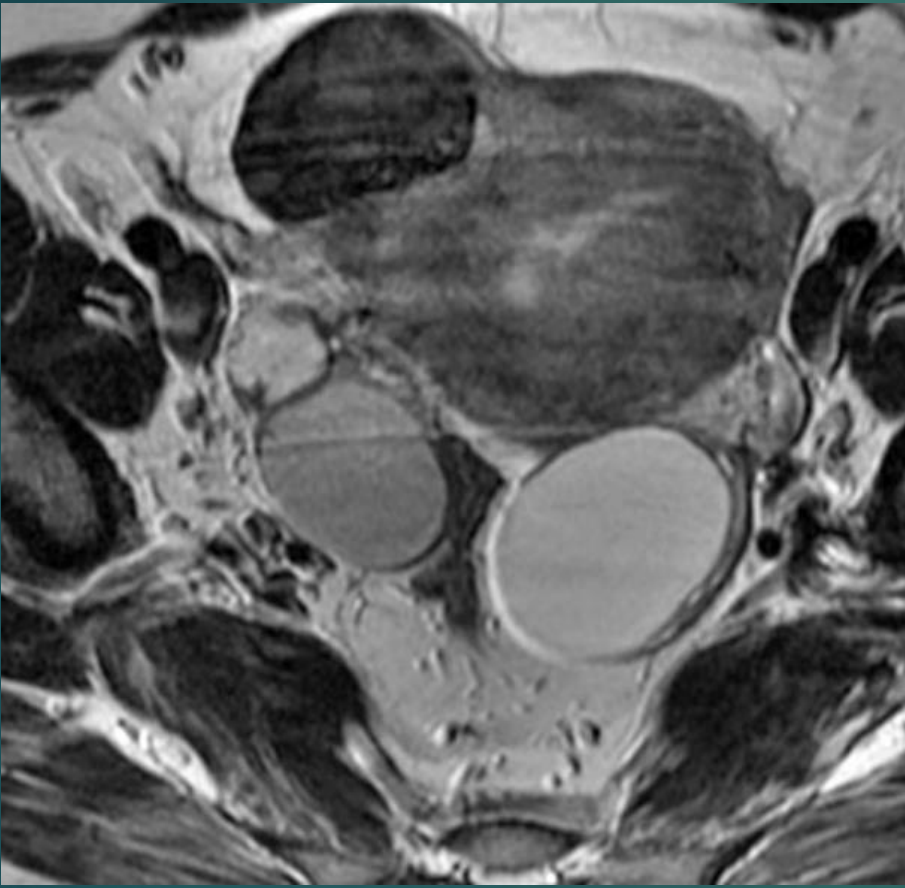
AKUT PYELONEFRIT

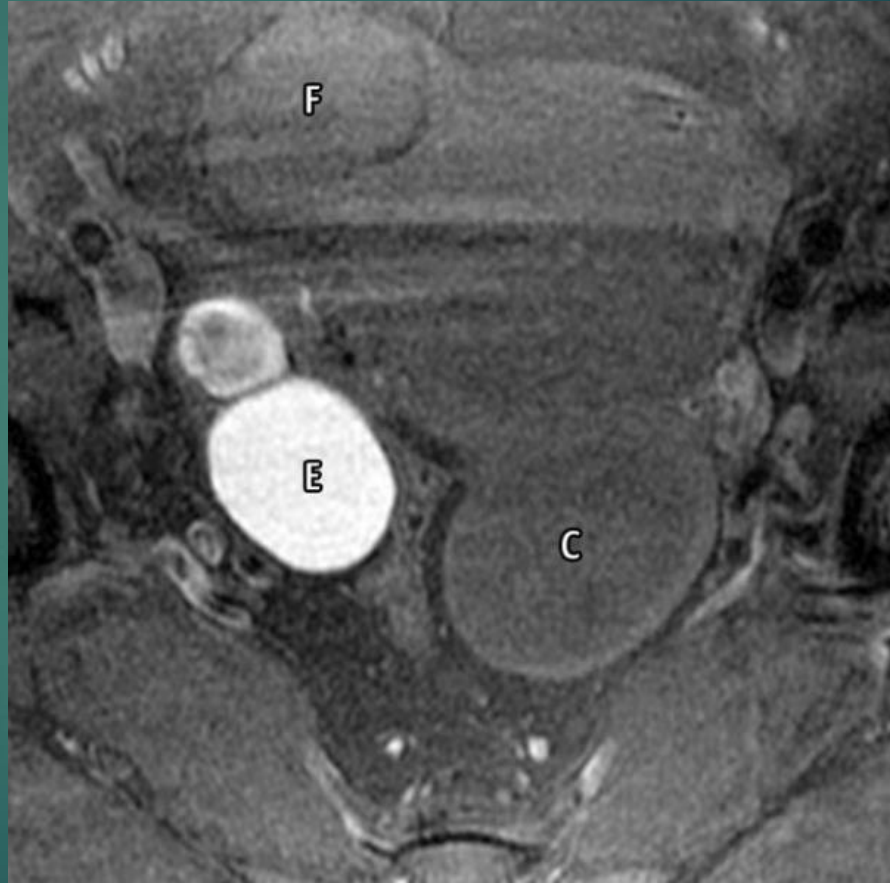
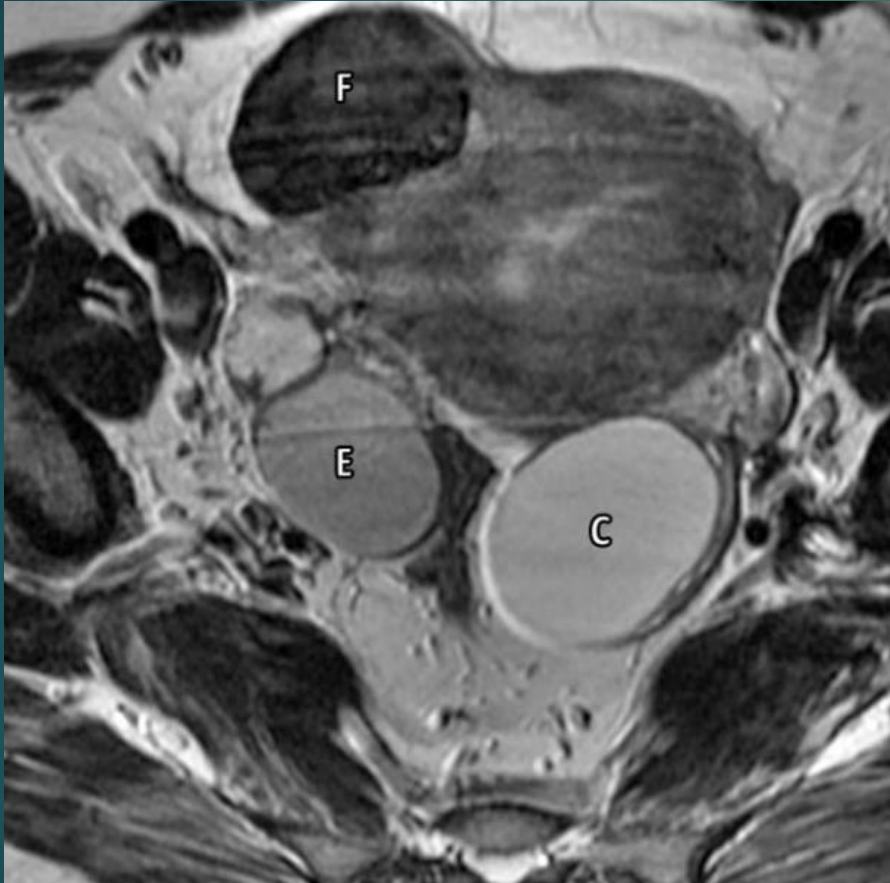


OVER TORSİYONU



VAKA







TEŞEKKÜRLER.....